

# DOPPLER BASED COMPARISON OF TRANSIENT SYNOVITIS OF THE HIP JOINT AND PERTHES' DISEASE

Tauseef Raza<sup>1</sup>, Sergey Evtichievich Lvov<sup>2</sup>, Tatiana Valentinovna Burenkova<sup>3</sup>, Ejaz Ahmad Khan<sup>4</sup>,  
Aleksai Yurevich Philosophov<sup>5</sup>

## ABSTRACT

**Objective:** To compare the hip joint perfusion (HJP) and hip joint effusion (HJE) of affected and unaffected joints of patients with Perthes disease (PD) and transient synovitis (TS) with the help of doppler ultrasound.

**Methodology:** This study was conducted at Children Clinical Hospital No. 1, Ivanovo, Russia from 01.09.2001 to 10.01.2006. One hundred and one children diagnosed as TS and PD were examined. Hip joint perfusion and hip joint effusion were measured on Doppler ultrasonic examinations, carried out with the help of duplex scanning of the vessels of the hip joints. Patient's data was analyzed statistically by SPSS 14.

**Results:** Out of 101 patients 59 (58.4%) children had doppler ultrasound evidence of PD, while 42 (41.6%) had TS of the hip joint. In TS, HJE was  $2.9 \pm 0.20$  ml and  $2.0 \pm 0.02$  ml in affected and unaffected joints respectively ( $p < 0.01$ ) while in PD HJE was significantly increased in stage 1, II and III. HJP of medial circumflex arteries, lateral circumflex arteries, lateral ascending cervical artery and intra capsular ring was significantly decreased in affected joints of TS and PD. Increased circumflex venous flow was observed in TS and first 3 stages of PD. Three children with TS subsequently developed PD.

**Conclusion:** Increased joint effusion is the common factor causing deterioration of perfusion both in children with TS and PD. Increased effusion in perfusion deficit hip joints may lead to development of PD in children with TS. Early diagnostic sign of the beginning of PD is subcompensated perfusion deficiency of the femoral head.

**Keywords:** Transient Synovitis, Perthes Disease, Doppler Ultrasound, Hip Joint Perfusion.

**This article may be cited as:** Raza T, Lvov SE, Burenkova TV, Khan EA, Philosophov AY. Doppler based comparison of Transient Synovitis of the hip joint and Perthes' Disease. Khyber Med Univ J 2012;4(1): 2-8

## INTRODUCTION

Legg-Calvé-Perthes disease is a childhood hip disorder associated with ischemic necrosis of the growing femoral head<sup>1</sup>. Perthes disease (PD) is usually idiopathic, although the etiology and pathogenesis is still controversial<sup>1-4</sup>. The main component in development of

Perthes' disease is disturbance of blood supply in children, at the age of 3-7 years when the vascular network starts to transform from postnatal to the adult type<sup>5,6</sup>. The hip joint at the age of 3-9 years gets perfusion mainly from medial circumflex arteries (MCA) and lateral circumflex arteries (LCA) of the hip. Other vessels- arteries of ligamentum teres, inferior and superior gluteal arteries, the perforating and obturator artery at this age play an insignificant role<sup>7</sup>. MCA and LCA form two collateral ring systems: one (extracapsular) ring is located outside the capsule, at the base of the femoral neck, second (intracapsular) ring - under synovial membrane, inside the capsule on the border of the articular cartilage and neck of the femur. Extra capsular ring is formed by the MCA and LCA of the hip. From this ring through the articular capsule penetrate 4 ascending cervical arteries, originating from MCA, whereas, anterior ascending cervical artery originate from LCA. These arteries in turn form intra capsular ring, which is encountered 4 times less often in boys than in girls. These ascending cervical arteries become epiphyseal and metaphyseal arteries of the femur<sup>8</sup>. In PD there is marked decrease in the number of epiphyseal arteries at the age of 3-9 years that can lead to subcritical blood supply in this age group<sup>9-11</sup>.

There are very few studies regarding the relation between transient synovitis (TS) and PD, both of which have the common beginning – the synovitis<sup>12-14</sup>. Both dis-

- 1 Assistant Professor & In charge Department of Orthopaedics, Khyber Medical University (KMU) Institute of Medical Sciences, Kohat, Pakistan
- 2 Head of the department of Orthopaedics Ivanovo State Medical Academy, Russia.
- 3 Radiologist Department of Radiology Ivanovo State Medical Academy, Russia.
- 4 Assistant Professor, Department of Community Medicine, KMU Institute of Medical Sciences, Kohat, Pakistan.
- 5 In charge Orthopaedic Ward Children Clinical Hospital No 1, Ivanovo, Russia

### Address for correspondence:

**Dr. Tauseef Raza**

Assistant Professor & In charge Department of Orthopaedics  
Khyber Medical University (KMU) Institute of Medical Sciences, Kohat, Pakistan

Email: drtauseefraza@gmail.com

**Date Submitted:** September 21, 2011

**Date Revised:** March 03, 2012

**Date Accepted:** March 05, 2012

eases can be due to many idiopathic reasons but majority of researchers agree upon overcrowding and lower social economic conditions. Presence of synovitis is an obligatory condition in the pathogenesis of both diseases. According to some authors, the TS may be a predisposing factor for development of PD<sup>15-17</sup>.

PD constitutes 25-27 % of diseases of the hip joint and 3% of all pathology of the locomotor system in children<sup>9,14</sup>. Unfortunately, the diagnosis of PD is carried out basically in late stages of disease when irreversible changes in the head of femur have aroused and then the most careful and competent treatment does not give full recovery. As a result the amount of failures reaches 40-80%, patients develop early coxarthrosis and become disabled at a young age<sup>15,18</sup>. Very few studies have been conducted regarding early diagnosis of Perthes disease with the help of Doppler ultrasound<sup>7,19,20</sup>. The vascularization of the femoral head in TS and PD has not been well studied on Doppler images<sup>21-23</sup>. On the other hand these diseases have been well studied with the help of ultrasound alone<sup>24-27</sup>.

The purpose of the study was to compare the hip joint perfusion (HJP) and hip joint effusion (HJE) of affected and unaffected joints of patients with PD and TS with the help of doppler ultrasound.

## METHODOLOGY

This descriptive analytical study was conducted in the department of traumatology and Orthopedics, Children Clinical Hospital No. 1, Ivanovo, Russia from 01.09.2001 - 10.01.2006. Total of 101 children of both genders including 59 admitted confirmed cases of Perthes disease and 42 of Transient Synovitis (TS) were included in the study. Age of patients with Perthes disease ranged from 5 to 14 years (mean age: 6.46 years), and 3 to 9 years (mean age: 5.73 years) in Transient Synovitis. All Children suffering from any other acute or chronic diseases of the hip joint were excluded from the study. All consecutive cases were referred to radiology department for Doppler ultrasound examination of the affected and unaffected hip joints. Convenient sampling method was used to collect the data. Informed consent was taken and the study was duly approved by the ethical committee of hospital. Data was collected on a specially designed proforma.

Doppler ultrasound was carried out with the help of duplex scanning on Aloka 1400 and Sonosite units by using Convective and sector gauges with frequency from 3.5 – 7.5 MHz. The Doppler examination was limited to 10-15 minutes for each hip and was performed by single investigator. Examination included duplex scanning of the vessels of the hip joint, with use of color mapping in power and convergent modes and spectral dopplerography. Doppler ultrasound examination was conducted in supine and lateral positions. In supine position examination was conducted along standard planes: 1.0 -1.5 cm parallel and below inguinal ligament

and along the projection of the neck of femur. Following parameter was assessed: *hip effusion* (HE) in ml. In lateral position the hip and knee joints of the patient were flexed to 90°. Assessment was done in the frontal plane with the sensor placed over the region of greater trochanter. Following parameters were assessed in this position: condition of medial circumflex artery (MCA), lateral circumflex artery (LCA) and lateral ascending cervical artery (LACA). Condition of intra capsular ring (ICR) and venous blood flow were assessed in both positions.

For statistical comparison of degrees of changes within medial and lateral circumflex arteries, and their branches, coefficients were used:

1.0 – blood flow not present

0.5 - blood flow not sufficient

0 – normal blood flow

In case of intra capsular ring:

1.0 – absence of ring

0.5 – incomplete ring

0 – complete ring

Similar coefficients have been used, for an estimation of venous system:

Increased blood flow of circumflex veins – 1

Absence of increased venous blood flow – 0

All the findings were documented on proforma and were subjected to statistical analysis by using software SPSS version 14.0 and, p value of < 0.05 was considered significant.

## RESULTS

By analyzing data of 101 doppler ultrasounds, 59 (58.4%) patients with Perthes' disease and 42 (41.6%) with TS. Table I is showing the details of parameters of doppler ultrasound on normal and affected hip joints in TS and PD. In patients with TS, a significant increase in volume of HJE was observed in affected joints of transient Synovitis ( $2.9 \pm 0.20$ ) as compared to unaffected side ( $2.02 \pm 0.02$ ). In Perthes' disease the volume of HJE was depending upon the stage I of disease. The maximal increase was observed in stage I<sup>22</sup> ( $3.5 \pm 0.2$  ml) in comparison with unaffected side ( $2.5 \pm 0.06$  ml).

Doppler ultrasound revealed, disturbance of blood supply of the head of femur in 11 patients out of 42 with transient synovitis (Fig. 1). The disturbance of blood supply was in the form of hypoplasia and aplasia of vessels. Incomplete arterial ring was encountered on the normal side as well in some cases. Change in degree of coefficient constitute in case of MCA constitutes ( $0.16 \pm 0.04$ ), its branch LACA ( $0.22 \pm 0.06$ ;  $p < 0.01$ ), in case of LCA ( $0.13 \pm 0.04$ ), and ICR ( $0.17 \pm 0.08$ ;  $p < 0.05$ ).

**PARAMETERS OF DOPPLER ULTRASOUND ON NORMAL (N) AND AFFECTED (A) HIP JOINTS IN CHILDREN WITH TRANSIENT SYNOVITIS (N=42) AND PERTHES' DISEASE (N=59)**

Parameter	TS (n=42)		PD stage I (n=22)		PD stage II (n=21)		PD stage III (n=8)		PD stage IV (n=8)	
	N	A	N	A	N	A	N	A	N	A
HJE (ml)	2.0 ± 0.02	2.9 ± 0.20	2.5 ± 0.06	3.5 ± 0.20	2.2 ± 0.09	3.2 ± 0.12	1.2 ± 0.14	1.9 ± 0.20	0.8 ± 0.12	0.9 ± 0.16
p value	< 0.01		< 0.05		< 0.05		< 0.05		> 0.05	
MCA	0.1 ± 0.03	0.5 ± 0.04	0.4 ± 0.06	0.8 ± 0.08	0.18 ± 0.05	0.68 ± 0.16	0.2 ± 0.04	0.88 ± 0.11	0.2 ± 0.03	0.5 ± 0.09
p value	< 0.05		< 0.01		< 0.01		< 0.01		< 0.05	
LCA	0.1 ± 0.01	0.4 ± 0.03	0.2 ± 0.05	0.5 ± 0.07	0.2 ± 0.06	0.7 ± 0.16	0.2 ± 0.03	0.6 ± 0.13	0.1 ± 0.02	0.4 ± 0.10
p value	< 0.05		< 0.05		< 0.01		< 0.01		< 0.05	
LACA	0.2 ± 0.02	0.5 ± 0.06	0.3 ± 0.04	0.8 ± 0.09	0.3 ± 0.07	0.9 ± 0.15	0.2 ± 0.05	0.8 ± 0.12	0.2 ± 0.04	0.6 ± 0.11
p value	< 0.05		< 0.05		< 0.01		< 0.01		< 0.05	
ICR	0.1 ± 0.02	0.5 ± 0.02	0.4 ± 0.06	0.7 ± 0.08	0.5 ± 0.09	0.9 ± 0.07	0.3 ± 0.04	0.93 ± 0.06	0.1 ± 0.03	0.6 ± 0.11
p value	< 0.05		< 0.05		< 0.01		< 0.01		< 0.05	
IBFCV	0.2 ± 0.04	0.6 ± 0.05	0.3 ± 0.07	0.8 ± 0.12	0.4 ± 0.08	0.7 ± 0.16	0.2 ± 0.05	0.6 ± 0.14	0.1 ± 0.02	0.1 ± 0.03
p value	< 0.05		< 0.01		< 0.01		< 0.05		> 0.05	

Table I

HJE=Hip joint effusion; MCA= medial circumflex arteries , LCA=lateral circumflex arteries ; LACA=lateral ascending cervical artery ICR=intra capsular ring, IBFCV= Increased blood flow circumflex veins, PD= Perthes disease

## DOPPLER ULTRASOUND STAGES OF PERTHES DISEASE

Parameters	Subcompensation 0 stage	Decompensation I stage	Deformation II stage	Initial stage of restoration III stage	Final stage of restoration IV stage
Hip Effusion	Increased	Increased	Slightly in- creased	Decreased	Decreased
Hip perfusion	Subcompensated	Decompensated	Absent	Collateral circulation	Restoration of circulation
Venous blood- flow	Increased	Increased	Mild In- creased	Dilated lumen of veins	Return to normal

Table II

## DOPPLER SCAN OF A 7 YEAR OLD BOY WITH TRANSIENT SYNOVITIS OF THE HIP JOINT SHOWING STENOSIS OF THE MEDIAL CIRCUMFLEX ARTERY

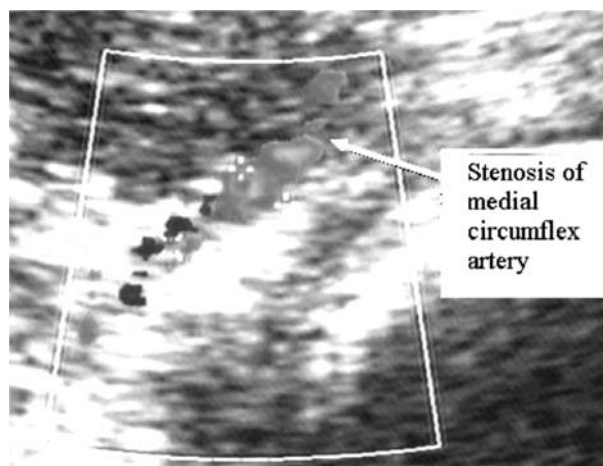


Fig. 1

## CHANGES IN DEGREE OF COEFFICIENT OF MEDIAL CIRCUMFLEX ARTERY OF CHILDREN WITH PERTHES' DISEASE

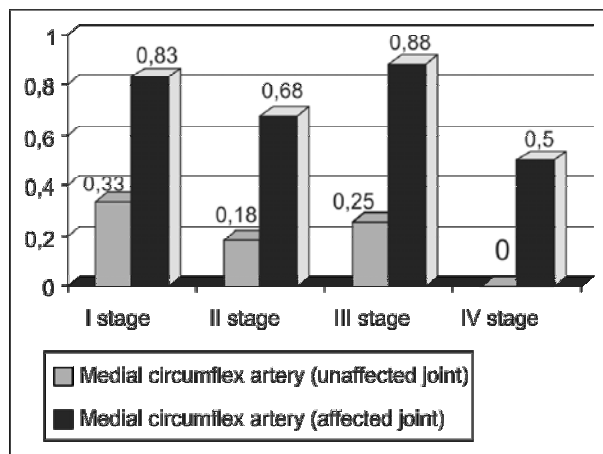


Fig. 2

## CHANGE IN DEGREE OF COEFFICIENT OF MEDIAL AND LATERAL CIRCUMFLEX ARTERY OF CHILDREN WITH PD

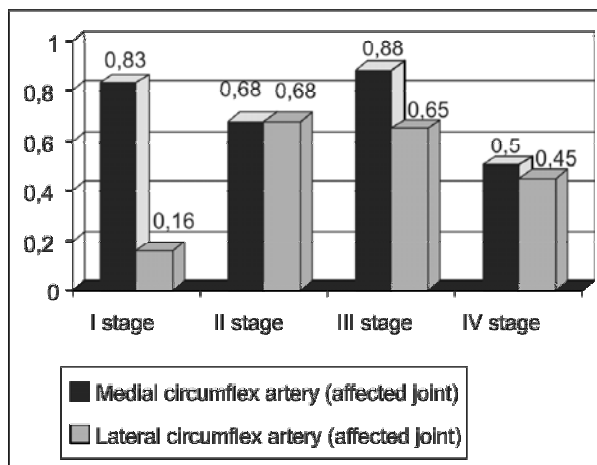


Fig. 3

The important diagnostic feature in children with transient synovitis was increased venous blood flow in circumflex veins ( $0.22 \pm 0.05$ ;  $p < 0.01$ ), which was in the form of dilatation of circumflex veins and decrease in venous outflow. Three of these children subsequently developed Perthes' disease.

In children with Perthes' disease change in degree of coefficient of MCA depends upon the stage of PD (Fig. 2). In II and III stages of Perthes' disease, there was marked hypoplasia and aplasia of MCA, change in degree of coefficient constituted  $0.68 \pm 0.16$  and  $0.88 \pm 0.11$  accordingly, in comparison with the unaffected side  $0.18 \pm 0.13$  and  $0.25 \pm 0.16$ ;  $p < 0.01$ ). LCA, and LACA too have been changed depending upon the stage of illness ( $p < 0.01$ ) and constituted ( $0.7 \pm 0.16$ ;  $0.90 \pm 0.16$ ) at II stage and ( $0.65 \pm 0.13$ ;  $0.83 \pm 0.16$ ) at III stage.

ICR has a significant change in degree of coefficient depending upon the stage of Perthes' disease and constituted ( $0.91 \pm 0.08$ ;  $0.93 \pm 0.06$ ) in II and III stages respectively.

Difference in change in degree of coefficient between MCA and LCA is evident from Fig. 3. Disturbance of venous blood supply in Perthes' disease manifested as increased venous blood flow, change in degree of coefficient constitute ( $0.68 \pm 0.16$ ; and  $0.75 \pm 0.16$   $p < 0.01$ ) in II and III stages of Perthes' disease, because of dilatation of circumflex veins of the femur, and reduction in venous outflow. Change of spectrum of arterial and venous blood flow was in the form of high amplitude of systolic peaks, and decreased during the process of progression of disease. The data of received changes is mentioned in Table I.

## DISCUSSION

The analysis of results shows that children with Transient Synovitis who subsequently developed Perthes disease, and those with the initial stages of Perthes' disease are practically identical. According to Wingstrand et al,<sup>17</sup> increased intracapsular pressure, usually present in TS of the hip joint may cause femoral head ischemia and necrosis. Other studies have shown that synovitis plays an important role in the pathogenesis of both these diseases<sup>18,28,29</sup>. It means that children with TS, in whom subcompensated perfusion deficiency of the femoral head and increased amount of hip effusion are present can be at risk of developing Perthes' disease. However Futami T et al have reported that though wide joint spaces were found in both TS and PD but in TS the capsular distension was due to synovial effusion and in PD the wide space was the result of thickened synovial membrane<sup>30</sup>. Joint effusion can be accurately measured on noninvasive ultrasonography<sup>31</sup>. However for assessment of femoral vascularity in PD, specific scanning planes of coloured Doppler sonography are required<sup>32</sup>.

Alpaslan AM et al<sup>33</sup>, in their experimental study showed that interruption of the blood supply of femoral head in animals produced changes in the femoral head similar to Legg-Calvé-Perthes disease. In children with Perthes' disease blood circulation of the hip joint was either subcompensated or decompensated. Perfusion deficiency of the head of femur, was caused by hypoplasia and aplasia of the vessels of the hip joint, their occlusion, incomplete or absence of ICR at the edge of articular cartilage. Our findings confirm the findings of insufficient blood supply in this age group by Wertheimer<sup>34</sup> and Atsumi<sup>35</sup>. There was significant deficiency at the posterior aspect of the ICR, which originates from the ascending branches of MCA, and was the cause of disturbance of blood circulation in MCA. In some cases (3 children at II stage; and 2 children at III stage) hypoplasia and aplasia of the vessels, incomplete or absence of ICR were discovered and on the unaffected side as well. It proves the findings of Wertheimer<sup>34</sup> of

incomplete intra capsular rings, especially in boys. This may be one of the reasons that Perthes' disease is encountered more commonly in boys.

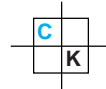
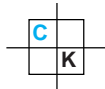
PD is classified into four stages of involvement of the femoral head epiphysis comprising of subchondral fracture, fragmentation, re-ossification and healing with residual deformity (Remodeling)<sup>36</sup>. However, the Doppler ultrasound findings may be utilized in revising the existing classification of Perthes disease by adding a new stage i.e. "subcompensation stage". As findings of a single study cannot be generalized, more advanced studies are needed for the proposed change in the classification of PD. We need to evaluate the children with transient synovitis for inherent symptoms of subcompensation stage of Perthes' disease. Following factors may be taken into account for the this stage.

1. increase in volume of hip effusion;
2. at color mapping sub- or decompensated perfusion deficiency of the hip joint as absent or deficient blood flow at the level of ICR, ascending cervical branches of medial and lateral circumflex arteries, caused by occlusion in combination with hypoplasia and aplasia;
3. increase in venous blood flow basically because of dilatation of circumflex veins.

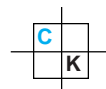
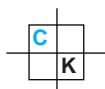
Thus, we conclude that increase joint effusion is the common factor causing deterioration of perfusion both in children with Transient synovitis and Perthes disease. Synovitis due to trauma or any other cause and increased effusion in perfusion deficit hip joints may lead to development of Perthes disease in children with Transient Synovitis. Early diagnostic attribute of the beginning of Perthes disease is subcompensated perfusion deficiency of the femoral head. However further large scale and advanced studies are needed for establishing Transient synovitis as a risk factor for developing Perthes disease.

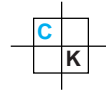
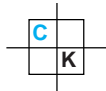
## REFERENCES

1. Kim HKW. Legg-Calvé-Perthes Disease. J Am Acad Orthop Surg 2010; 18(11): 676-86.
2. Yehudith AD, Christopher C, Adam G, Yehuda S; Gershwin ME. Pathogenesis and natural history of osteonecrosis. Seminars in Arthritis and Rheumatism 2002 Oct; 32 (2): 94-124.
3. Eric G, Schoenecker J, Perry L, Osland A, John DC, Dobbs A. et al. Smoking and socio-economic status in the etiology and severity of Legg-Calvé-Perthes' disease. J Pediatr Orthoped 2004; 13 (6): 367-70.
4. Harry KWK, John AH. Pathophysiology, Classifications, and natural history of Perthes disease. Orthoped Clin North Am: 2011; 42(3): 285-95.



5. Henk E. Towards a better understanding of the aetiology of Legg–Calvé–Perthes’ disease: Acetabular retroversion may cause abnormal loading of dorsal femoral head–neck junction with restricted blood supply to the femoral epiphysis. *Medical Hypotheses* 2007; 68 (5): 995-7.
6. Johanne ED, Susan AC, Leonard PC, Young JK, Diego JDiego Jaramillo . MR Imaging of Congenital/developmental and acquired disorders of the pediatric hip and pelvis. *Mag Reson Imag Clin North Am* 2005; 13(4): 783-97.
7. Xue M.Q, Kun Z, Qiao W, Yi T, XiAO JJ, Ming L. et al. Evaluating the Hip Joints’ Blood Flow of Perthes’ Disease with Ultrasonography. *Ultrasound Med Biol* 2009; 35(8): S68.
8. Berenshtejn SS. Condition of microcirculation in osteochondropathy of femoral head in children. *Orthop Traumatol* 1993; 4: 57.
9. Wainwright AM., Benson MKD. Legg–Calvé–Perthes’ disease. *Current Orthop J* 2001; 15 (2): 127-34.
10. Dimeglio A, Canavese F. Imaging in Legg-Calvé-Perthes disease. *Orthop Clin North Am* 2011; 42 (3): 297-302.
11. Jerry RD. The Hip: MR Imaging of Uniquely pediatric disorders. *Radiol Clin North Am* 2009; 47 (6): 997-1008.
12. Chell J, Dhar S. Perthes disease. *Surgery (Medicine Publishing)* 2007; 25(4): 181-3.
13. Daniel P, Colin B. Hip disorders in childhood. *Surgery (Medicine Publishing)* 2011; 29 (4): 181-6.
14. Mark SG, Alistair WM. The limping child. *The Foundation Years* December 2008; 4(8): 319-23.
15. Zacher J, Gursche A. ‘Hip’ pain. *Best Pract Res Clin Rheumatol* 2003; 17(1): 71-85.
16. Hochbergs P, Eckerwall G, Egund N, Jonsson K, Wingstrand H. Synovitis in Legg-Calve-Perthes disease. Evaluation with MR imaging in 84 hips. *Acta Radiol* 1998; 39(5): 532-37.
17. Wingstrand H. Significance of synovitis in Legg-Calve-Perthes disease. *J Pediatr Orthop B* 1999; 8(3): 156-60.
18. Fischer SU, Beattie TF. The limping child: epidemiology, assessment and outcome. *J Bone Joint Surg Br* 1999; 81(6): 1029-34.
19. Doria AS, Guarniero R, Molnar LJ, Modena M, Cunha SG, de Godoy JRM et al Three dimensional (3D) contrast enhanced power doppler imaging in Legg-Calve-Perthes disease. *Pediatr Radiol* 2000; 30(12): 871-74.
20. Joshua F, Edmonds J, Lassere M. Power doppler ultrasound in musculoskeletal disease: A Systematic Review. *Seminars in Arthritis and Rheumatism* 2006; 36 (2): 99-108.
21. Robben SG, Lequin MH, Diepstraten AF, Hop WC, Meradji M. Doppler sonography of the anterior ascending cervical arteries of the hip: evaluation of healthy and painful hips in children. *AJR Am J Roentgenol* 2000; 174(6): 1629-34.
22. Sofka, Carolyn MMD. Legg-Calve-Perthes disease: Multipositional Power Doppler Sonography of the Proximal Femoral Vascularity. *Ultrasound Quarterly* 2008; 4(2): 125.
23. Doria AS, Guarniero R, Cunha FG, Modena M, De Godoy RM Jr, Luzo C et al. Contrast-enhanced power doppler sonography: assessment of revascularization flow in Legg-Calvé-Perthes’ disease. *Ultrasound Med Biol* 2002; 28(2): 171-82.
24. Bosch R, Niedermeier C, Heimkes B. Value of ultrasound in differential diagnosis of pediatric hip joint effusion. Perthes disease, C. fugax, epiphysiolysis coapitis femoris. *Z Orthop Ihre Grenzgeb* 1998; 136(5): 412-19.
25. Eggel H., Drekonja T, Kaiser B, Dorn U. Ultrasonography in the diagnosis of transient synovitis of the hip and Legg-Calve-Perthes disease. *J Pediatr Orthop B* 1999; 8(3): 177-80.
26. Konermann W, Gruber G, Gaa J. Standardized sono-graphic examination of the hip joint. *Ultraschall Med* 2000; 21(3): 137-41.
27. Robben SG, Meradji M, Diepstraten AF, Hop WC. US of the painful hip in childhood: diagnostic value of cartilage thickening and muscle atrophy in the detection of Perthes disease. *Radiol* 1998; 208(1): 35-42.
28. Alf AB, Colin EB. The persistently irritable joint in childhood: An orthopaedic perspective. *Eur J Radiol* 2000; 33(2): 135-48.
29. Benjamin J. Prognostic factors and outcome measures in Perthe’s disease. *Orthop Clin North Am* 2011; 42(3): 303-15.
30. Futami T, Kasahara Y, Suzuki S, Ushikubo S, Tsuchiya T. Ultrasonography in transient synovitis and early Perthes’ disease. *J Bone Joint Surg Br.* 1991; 73: 635-9.
31. Yabunaka K, Ohue M, Morimoto N, Kitano N, Shinohara K, Takamura M, et al. Sonographic measurement of transient synovitis in children: diagnostic value of joint effusion. *Radiol Phys Technol* (2012) 5: 15-19.
32. Doria AS, Cunha FG, Modena M, Maciel R, Molnar LJ, Luzo C, et al. Legg-Calvé-Perthes disease: multi-positional power Doppler sonography of the proximal femoral vascularity.





33. Alpaslan AM, Aksoy MC Yazici M. Interruption of the blood supply of femoral head: an experimental study on the pathogenesis of Legg-Calve-Perthes Disease. Archives Orthop Trauma Surg 2007; 127(6): 485-91.
34. Wertheimer LG, Lopes Sde L. Arterial supply of the femoral head. A combined angiographic and histological study. J Bone Joint Surg (Am) 1971; 53: 545-556.
35. Atsumi T, Yamano K, Muraki M, Yoshihara S, Kajihara T. The blood supply of the lateral epiphyseal arteries in Perthes' disease. J Bone Joint Surg [Br] 2000; 82-B: 392-8.
36. Miyamoto Y, Matsuda T, Kitoh H, Haga N, Ohashi H, Nishimura G. et al. A recurrent mutation in type II collagen gene causes Legg-Calvé-Perthes disease in a Japanese family. HUMAN GENETICS 2007; 121(5): 625-9.

#### AUTHOR'S CONTRIBUTION

Following authors have made substantial contributions to the manuscript as under

**TR:** Drafting the manuscript and Critical revision

**SVL:** Conception and design, Analysis and interpretation of data

**TVB:** Acquisition of data

**EAK & AYP:** Drafting the manuscript

#### CONFLICT OF INTEREST

Authors declare no conflict of interest

#### GRANT SUPPORT AND FINANCIAL DISCLOSURE

NONE DECLARED

KMUJ web address: [www.kmu.j.kmu.edu.pk](http://www.kmu.j.kmu.edu.pk)

Email address: [kmuj@kmu.edu.pk](mailto:kmuj@kmu.edu.pk)

