

WILSON'S DISEASE: A BRIEF REVIEW

Nuzhat Choudhury¹, Mamun-Al-Mahtab², Shafiquel Islam¹

ABSTRACT

Although first described in the early 1900s, the pathogenesis of Wilson's disease was identified in the mid-1900s. It is an inherited error of copper metabolism that predominantly presents with hepatic and/or neurological manifestations. Hepatic form of Wilson's disease can have varied presentations from acute hepatitis to liver cirrhosis and end stage liver disease necessitating liver transplantation. In addition to the liver and brain other organs like eyes, kidneys and bones are frequently involved. Although infrequent, Wilson's disease is not rare in Neuromedicine, Hepatology and Ophthalmology practices. Chelation therapy remains the mainstay of treatment and several copper chelating agents are now available.

This article may be cited as: Choudhury N, Mahtab MA, Islam S. Wilson's disease: A brief review. KUST Med J 2011; 3(1): 24-27.

INTRODUCTION

In 1912, S.A. Kinnier Wilson, a Neurology resident described cirrhosis and lenticular degeneration occurring in families and this disease has been since named after him as Wilson's disease¹. J.N. Cumings first elucidated the link between copper and Wilson's disease in 1948². This is an inherited disorder of copper metabolism manifesting typically as hepatic disease in children and as neurological disease in older children and young adults.

PATHOPHYSIOLOGY

Copper overload in Wilson's disease occurs due to reduced biliary excretion of copper. ATP7B gene was identified as the defective gene causing the disease by three independent teams in 1993³⁻⁵. ATP7B protein is a membrane bound copper transporting P-type ATPase which transport copper out of the hepatocytes into bile for incorporation of copper into ceruloplasmin, which is then secreted into the bloodstream. H1069Q, the most common ATP7B mutation in the Caucasian population⁶.

CLINICAL FEATURES

Symptomatic Wilson's disease typically presents in children and young adults, though it has been reported from 2-70 years of age. The prevalence of Wilson's dis-

ease is estimated to be 1 in 50,000 in general population⁷. Being an autosomal recessive disorder, Wilson's disease occurs more frequently in children borne to parents of consanguineous marriage.

Hepatic presentation:

Hepatic involvement by Wilson's disease can present as acute (acute hepatitis, fulminant hepatic failure) or chronic liver disease (chronic hepatitis, cirrhosis). Hepatocellular carcinoma is a rare presentation. Coomb's negative hemolytic anemia may be associated with fulminant hepatic failure due to Wilson's disease; this is attributed to massive release of copper from hepatocytes into the circulation leading to intravascular hemolysis.

Neurological presentation:

Extrapyramidal features due to copper deposition in basal ganglia are the typical neurologic presentation. Dysarthria, dysphagia, apraxia and a tremor rigidity syndrome are seen. Deterioration of handwriting and drooling of saliva are some common presentation.

Ocular involvement:

Kayser Fleischer (KF) rings are golden brown or green rings due to copper deposits in peripheral part of Descemet's membrane of cornea which are best seen on slit lamp examination. It appears as a zone of granules that change colour under different types of illumination. KF rings are present in nearly all patients with Wilson's disease, preferentially in the vertical meridian and usually disappear with penicillamine therapy. Sunflower cataracts may also be seen.

Renal tubular acidosis:

Renal tubular acidosis maybe asymptomatic or may present as metabolic bone disease, renal stones or muscle weakness. Hypercalciuria, possibly due to tubular defect in calcium re-absorption and nephrocalcinosis can occur. Hypokalemia can present as muscle weakness⁸.

- 1 Department of Ophthalmology, Bangabandhu Sheikh Mujib Medical University, Dhaka, Bangladesh,
- 2 Department of Hepatology, Bangabandhu Sheikh Mujib Medical University, Dhaka, Bangladesh,

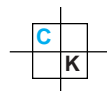
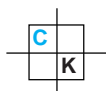
Address for Correspondence:

Dr. Nuzhat Choudhury, Assistant Professor
Department of Ophthalmology,
Bangabandhu Sheikh Mujib Medical University,
Dhaka, Bangladesh
Email: nuzhat@optimaxbd.net

Date Received: February 02, 2011

Date Revised: May 20, 2011

Date Accepted: June 6, 2011



Orthopedic involvement:

Osteoporosis is most frequent, but inflammatory changes in small joints, osteomalacia, premature osteoarthritis, spine osteochondritis, fractures and heterotopic ossification are the different orthopedic presentations seen in Wilson's disease⁹.

DIAGNOSIS

It is common to see a lag period between onset of symptoms and time of diagnosis in Wilson's disease. The key to early diagnosis of Wilson's disease is keeping a high index of clinical suspicion when unexplained hepatic or neurological or psychiatric illness occurs in childhood or early adulthood. Presence of Kayser Fleischer rings and/or low serum ceruloplasmin usually makes the diagnosis of Wilson's disease. Once a patient is diagnosed, the entire family should be screened to detect pre-symptomatic disease.

Serum ceruloplasmin

Ceruloplasmin is a copper carrying protein synthesised in the liver and secreted into the plasma. Defective ATP7B protein in Wilson's disease impairs incorporation of copper into ceruloplasmin, accounting for reduced serum ceruloplasmin levels. Ceruloplasmin is an acute phase reactant, thus serum levels can go up in inflammatory states, including hepatic inflammation. Serum ceruloplasmin levels can also be increased in hyper-estrogenic states like pregnancy and oral contraceptive use. Reduced serum ceruloplasmin levels may also be seen in advanced liver disease of different etiologies (probably reflecting reduced hepatic synthetic function), proteinuria, malabsorption, heterozygote carrier status of ATP7B gene mutation, aceruloplasminemia (caused by mutations of ceruloplasmin gene) and Menke's disease (X-linked disorder of copper transport due to mutations of ATP7A gene). Despite all these inadequacies, serum ceruloplasmin is a first line investigation done to diagnose Wilson's disease.

Serum copper

Serum copper levels are usually reduced in Wilson's disease (in proportion to reduced serum ceruloplasmin). However, free copper (which is not bound to ceruloplasmin) levels are high in most of the patients with Wilson's disease.

Urinary copper

Urinary copper is a reflection of free copper in the circulation. Measuring urine copper is useful in diagnosis of Wilson's disease and can be used as a measure of compliance to therapy.

Hepatic copper estimation

Though dry weight estimation of hepatic copper is the gold standard to diagnose Wilson's disease, low val-

ues (due to sampling variability) can occur in significant hepatic fibrosis / cirrhosis due to Wilson's disease¹⁰. High values can occur in chronic cholestatic liver disorders.

Liver histology

Histological changes are not diagnostic, but can suggest a diagnosis of Wilson's disease. Glycogenated nuclei, macro and microvesicular steatosis, portal infiltrate, Mallory bodies, chronic hepatitis-like appearance and cirrhosis are some of the histological changes seen in Wilson's disease. The histological picture can mimic autoimmune hepatitis and non-alcoholic steatohepatitis.

Genetic studies

The large number of ATP7B mutations known to cause Wilson's disease and the fact that majority of patients are compound heterozygotes (harbouring a different mutation on each allele) mean that genetic tests cannot be applied to diagnose Wilson's disease in routine clinical practice. However genetic tests are the method of choice to rule out disease within other family members. Genetic tests are done on DNA extracted from peripheral white blood cells, though it is possible to do this on liver biopsy samples as well.

TREATMENT (Table I)

Aim of treatment is to achieve normal copper levels in the body in the shortest possible time and to maintain it. Of the drugs used to treat Wilson's disease, Penicillamine and Trientine mainly act by increasing cupriuresis, while oral Zinc mainly acts by inhibiting copper absorption from the intestine¹¹. The commonly recommended regime is initial treatment with copper chelators like penicillamine or trientine to normalise copper levels in the body, followed by maintenance treatment with lower dose of copper chelators or zinc.

Transition from the initial high dose chelator therapy to maintenance therapy is made once patient is clinically well, has normal liver function tests, normal non-cerulo-

TREATMENT OF WILSON'S DISEASE

Treatment	Indications	Adverse Events
Chelators		
D-penicillamine	Initial and maintenance therapy	++
Trientine	Initial and maintenance therapy	+
Zinc acetate	Maintenance therapy	+
Liver transplantation	End stage liver disease	

Table I

plasmin bound copper level and 24 hour urine copper of 200-500 µgm per day on treatment. Treatment needs to be continued lifelong. Measuring 24 hour's urine copper excretion while on treatment is useful to monitor compliance.

Penicillamine

This was introduced in 1956 by Walshe as treatment for Wilson's disease and has remained the mainstay of treatment. Penicillamine reduces copper bound to protein and facilitates copper binding to Penicillamine, which is then excreted in urine.

A dose of 1000-1500 mg per day in 2-4 divided doses is used in the initial phase of treatment in adults (for at least 4-6 months). Treatment is started at smaller doses and dosage is gradually increased over time in an attempt to reduce the incidence of early adverse effects. A lower dose (750-1000 mg per day in 2 divided doses) is used in maintenance phase of treatment. In children, a dose of 20 mg per kg per day is used in 2-3 divided doses. Pyridoxine (vitamin B6) 25 mg per day should be given along with penicillamine to avoid pyridoxine deficiency.

Adverse effects of Penicillamine are reported in upto 30% of patients. The 2 broad classes of adverse effects are: immune mediated adverse effects (usually occur within first 3 months of treatment and need immediate cessation of treatment) and direct dose dependent adverse effects. Immune mediated adverse effects include fever, rash, lymphadenopathy, leukopenia, thrombocytopenia, lupus like syndrome, immune complex nephritis, pemphigus, buccal ulcerations, myasthenia gravis, Good Pasture's syndrome and optic neuritis. Direct adverse effects are pyridoxine deficiency, interference with collagen and elastin formation leading to skin lesions like cutis laxa and elastosis perforans serpiginosa¹².

Patients need close monitoring (clinical examination, complete blood count, urine analysis, serum creatinine) in the initial 6 weeks after commencing Penicillamine to monitor for early (immune mediated) side effects. If it is well tolerated, then monitoring can be made less frequent. In patients needing discontinuation of Penicillamine due to toxicity, other drugs like Trientine or zinc are tried. On initiation of Penicillamine for neurological Wilson's disease, worsening of neurological symptoms can occur in 10% of patients and new neurological symptoms may appear in a few patients¹³. This may be due to mobilization of hepatic copper stores leading to increased brain copper exposure or development of intracellular copper complexes. While these symptoms resolve in some patients on continuing the drug, other options are changing to other drugs like Trientine or zinc.

Abrupt discontinuation of Penicillamine is dangerous and has resulted in death or needed liver transplantation for liver failure.

Trientine

Trientine was introduced in treatment of Wilson's disease by Walshe in 1969. It acts mainly by increasing cupriuresis¹⁴. It appears to be as effective as Penicillamine and has fewer side effects. Reversible sideroblastic anemia may be a consequence of over-treatment. In adults, doses of 750-1000 mg per day are used in initial phase of treatment followed by 750 or 1000 mg per day in maintenance phase. In children a dose of 20 mg per kg per day in 2 or 3 divided doses is used. Trientine is used as primary therapy or as second line drug in patients who are intolerant to Penicillamine.

Zinc

The use of zinc in treating Wilson's disease was first reported in 1960's. Oral zinc interferes with intestinal absorption of copper primarily by inducing metallothionein in enterocytes, making them unavailable for systemic absorption. These metals are then excreted in feces with desquamated epithelial cells. Zinc also induces metallothionein in hepatocytes. The different oral zinc salts probably have similar ability to interfere with copper absorption, but may differ in tolerability. Zinc acetate, has least gastrointestinal side effects, while gluconate is more tolerable than sulfate. Dose of zinc acetate is upto 150 mg of elemental zinc per day in 3 divided doses in adults and older children and upto 75 mg per day in 3 divided doses in younger children.

Gastrointestinal upset is the commonest adverse effect. Elevation in serum amylase and lipase without clinical pancreatitis has been reported. Current practice is to use zinc as alternative therapy in patients who do not tolerate Penicillamine, in maintenance phase of treatment and first line treatment in asymptomatic Wilson's disease. It is not clearly known if combining zinc treatment with copper chelator is better than either alone.

Treatment during pregnancy

It is important to continue treatment during pregnancy to avoid the risk of precipitating potentially fatal liver failure on drug withdrawal. Limited data is available about the teratogenicity of Penicillamine and Trientine in general population¹⁵. Dose of Penicillamine and Trientine is however reduced to 25-50% of pre-pregnancy dose in third trimester as both the drugs may impair wound healing.

Diet

Dietary restriction of copper is insufficient as a sole therapy. It is advisable to reduce consumption of foods high in copper content, like shellfish, nuts, chocolate, mushrooms and organ meats in the first year of therapy.

Liver transplantation

Liver transplantation is treatment of choice in fulminant Wilson's disease and may be considered in pa-

tients with decompensated cirrhosis, non-responsive to medical therapy. Following liver transplantation hepatic insufficiency is corrected and neurological manifestations improve in up to 80% cases. Survival at 1 year is 80%.

Other agents

Ammonium tetrathiomolybdate appears to be useful as initial therapy in neurological Wilson's disease, however experience is very limited¹⁶. Antioxidants such as vitamin E may be useful adjuncts to treatment¹⁷. Dimer-caprol (British Anti-Lewisite) was the first drug used to treat Wilson's disease successfully, is rarely used now.

REFERENCES

1. SAK. Progressive lenticular degeneration: a familial nervous disease associated with cirrhosis of the liver. *Brain* 1912; 34: 295-307.
2. Cumings JN. The copper and iron content of brain and liver in the normal and in hepato-lenticular degeneration. *Brain* 1948; 71: 410-5.
3. Bull PC, Thomas GR, Rommens JM, Forbes JR, Cox DW. The Wilson disease gene is a putative copper transporting P-type ATPase similar to the Menkes gene. *Nat Genet* 1993; 5(4): 327-37.
4. Tanzi RE, Petrukhin K, Chernov I, Pellequer JL, Wasco W, Ross B, et al. The Wilson disease gene is a copper transporting ATPase with homology to the Menkes disease gene. *Nat Genet* 1993; 5(4): 344-50.
5. Yamaguchi Y, Heiny ME, Gitlin JD. Isolation and characterization of a human liver cDNA as a candidate gene for Wilson disease. *Biochem Biophys Res Commun* 1993; 197(1): 271-7.
6. Tsivkovskii R, Efremov RG, Lutsenko S. The role of the invariant His-1069 in folding and function of the Wilson's disease protein, the human copper-transporting ATPase ATP7B. *J Biol Chem* 2003; 278(15): 13302-8.
7. Frydman M. Genetic aspects of Wilson's disease. *J Gastroenterol Hepatol* 1990; 5(4): 483-90.
8. Chu CC, Huang CC, Chu NS. Recurrent hypokalemic muscle weakness as an initial manifestation of Wilson's disease. *Nephron* 1996; 73(3): 477-9.
9. Rodriguez Nieva N, Febrer Rotger A, Melendez Plumed M, Vernet Bori A. Osteoarthropathy in three siblings with Wilson's disease. *An Pediatr (Barc)* 2004 Aug; 61(2): 181-4.
10. Steindl P, Ferenci P, Dienes HP, Grimm G, Pabinger I, Madl C, et al. Wilson's disease in patients presenting with liver disease: A diagnostic challenge. *Gastroenterology* 1997; 113(1): 212-8.
11. Ferenci P, Steindl-Munda P, Vogel W, Jessner W, Gschwantler M, Stauber R. Diagnostic value of quantitative hepatic copper determination in patients with Wilson's Disease. *Clin Gastroenterol Hepatol* 2005; 3(8): 811-8.
12. Roberts EA, Schilsky ML. A practice guideline on Wilson disease. *Hepatology* 2003; 37(6): 1475-92.
13. Brewer GJ, Terry CA, Aisen AM, Hill GM. Worsening of neurologic syndrome in patients with Wilson's disease with initial penicillamine therapy. *Arch Neurol* 1987; 44(5): 490-3.
14. Walshe JM. The management of Wilson's disease with triethylene tetramine 2HC1 (Trien 2HC1). *Prog Clin Biol Res* 1979; 34: 271-80.
15. Sternlieb I. Wilson's disease and pregnancy. *Hepatology* 2000; 31(2): 531-2.
16. Brewer GJ, Askari F, Lorincz MT, Carlson M, Schilsky M, Kluin KJ, et al. Treatment of the neurologic presentation of Wilson disease. *Arch Neurol* 2006 Apr; 63(4): 521-7.
17. Sinha S, Christopher R, Arunodaya GR, Prashanth LK, Gopinath G, Swamy HS, et al. Is low serum tocopherol in Wilson's disease a significant symptom? *J Neurol Sci* 2005; 228(2): 121-3.

CONFLICT OF INTEREST

Authors declare no conflict of interest

GRANT SUPPORT AND FINANCIAL DISCLOSURE

NONE DECLARED