

THE ROLE OF FINE NEEDLE ASPIRATION CYTOLOGY (FNAC) IN THE MANAGEMENT OF SOLITARY THYROID NODULE

Khurshid Anwar¹, Iftikhar Ahmad Khan¹, Bakht Zada¹

ABSTRACT

Objective: To determine the sensitivity, specificity and diagnostic accuracy of fine needle aspiration cytology in the management of solitary thyroid nodule.

Material and Methods: This prospective study was conducted in the ENT Department, Hayatabad Medical Complex, Peshawar from January 1, 2007 to December 31, 2009. A total of 60 patients presenting with solitary thyroid nodule were included in the study. All the patients underwent fine needle aspiration of the nodule followed by excision biopsy. A comparison of FNA cytology and biopsy results was made.

Results: Mean age of patients was 35.7 ± 11.04 years with age ranged from 20 to 70 years. The male: female ratio was 1:4. The FNAC showed benign in 44 (77.3%), malignant in 8 (13.3%) and suspicious to be malignant in 8 (13.3%) cases and the biopsy revealed benign in 47 (78.3%) and malignant in 13 (21.7%) cases. The results obtained on FNAC were compared with those obtained from biopsying the respective specimens. The diagnostic value of FNAC in solitary thyroid nodule was; accuracy 88%, sensitivity 85%, specificity 90%, positive predictive value 69% and negative predictive value 95%.

Conclusion: FNA cytology is able to distinguish reliably between benign and malignant thyroid nodules. It is recommended to evaluate preoperatively every solitary thyroid nodule initially with the help of this technique. However in view of a small number of false negative results, the FNA results should be interpreted in the light of clinical findings. In case of doubt the true nature of the disease should be confirmed by biopsy.

Key Words: Solitary Thyroid Nodule, Fine Needle Aspiration Cytology, Histopathology, Sensitivity, Specificity.

This article may be cited as: Anwar K, Khan IA, Zada B. The role of fine needle aspiration cytology (FNAC) in the management of solitary thyroid nodule. KUST Med J 2010; 2(2): 49-52.

INTRODUCTION

A multitude of diagnostic tests like ultrasound, thyroid radionuclide scan and other imaging modalities are available to the clinician for evaluation of thyroid nodule but all are less effective in differentiating between benign and malignant conditions. FNAC has the ability to determine the nature of the lesion preoperatively and is considered the "gold standard" diagnostic test in the evaluation of a thyroid nodule.^{1,2} The prevalence of thyroid nodule ranges from 4% to 10% in the general adult population and from 0.2% to 1.2% in children³. The majority of clinically diagnosed solitary thyroid nodules are benign. However 20-40% of the nodules are malignant and require surgical resection⁴.

The success of FNAC lies in its ability to distinguish benign from malignant. A definitive tissue diagnosis allows planning of an appropriate treatment strategy. Lowhagen and colleagues believed that nearly 80% of patients with thyroid nodules can be spared surgical exploration on the basis of cytological diagnosis.⁵ There are few limitations of this method. Follicular adenoma and follicular carcinoma are difficult to diagnose. The distinction between reactive lymphoid hyperplasia and low grade lymphoma is also difficult. The problems of interpretation are largely due to the small amount of cellular material available for examination and the loss of normal tissue architecture as a result of aspiration.⁶

The advantages of FNA cytology are summed up in the acronym SAFE: it is Simple, Accurate, Fast, Economic, and, indeed, safe. Performed on an outpatient, this technique has the best safety record of any method of procuring tissue for a histopathological diagnosis. In contrast, surgical biopsy has potential risks associated with anaesthesia and surgery, along with the additional time required for healing⁷.

This study was conducted to determine the sensitivity, specificity and diagnostic accuracy of fine needle aspiration cytology in the management of solitary thyroid nodule in a tertiary care centre.

1. ENT Department, PGMI / Hayatabad Medical Complex, Peshawar, Khyber Pakhtunkhwa, Pakistan.

Address for Correspondence:

Dr. Khurshid Anwar

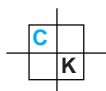
Medical Officer, ENT Department
PGMI/Hayatabad Medical Complex,
Peshawar, Pakistan.

Email: dr.khurshidanwar@yahoo.com

Date Received: May 07, 2010

Date Revised: December 13, 2010

Date Accepted: December 16, 2010



MATERIAL AND METHODS

This study was conducted in the ENT Department of Postgraduate Medical Institute, Hayatabad Medical Complex, Peshawar from January 1, 2007 to December 31, 2009.

Sample Size:

The study included 60 cases of solitary thyroid nodule.

Study Design:

It was a prospective, cross-sectional analytical study using the non-probability convenience sampling technique.

Inclusion Criteria:

1. Patients of all ages and both sexes.
2. All new and undiagnosed cases.

Exclusion Criteria:

1. Patients presenting with thyrotoxicosis and or hypothyroidism.
2. Patients presenting with multinodular goitres.
3. Patients with solitary thyroid nodules in whom surgery was not indicated.
4. Inconclusive aspirates.

Cases fulfilling the laid down criteria were included in the study. After obtaining informed consent, detailed history was taken. Clinical examination including indirect laryngoscopy of each case was carried out. All the cases had ultrasonographic examination of the thyroid gland and serum T3, T4 and TSH estimation before advising FNAC. Radionuclide scanning with Technetium 99 isotope was carried out in cases where the cytology report was 'adenoma' and 'follicular neoplasm'.

All the FNAs were performed by expert pathologists as outdoor procedures without administering any type of anaesthesia. The patients were admitted to the ward and all the biopsies were carried out as indoor procedures as part of the definitive treatment. The results obtained on FNAC were categorized into three categories, 'Benign', 'Malignant' and 'Suspicious'. A cytology report was labeled as "suspicious" when the diagnosis was adenoma, hyperplastic nodules, follicular neoplasm and Hurthle cell neoplasm. Considering the "Suspicious" cases on cytology as positive for malignancy, the results obtained on histopathological examination of the respective specimens were compared with those of FNAC. Final diagnosis was made on the basis of histopathological examination of biopsy which was categorized as either 'Benign' or 'Malignant'. The results were analyzed and the sensitivity, specificity, positive predictive value (PPV) & negative predictive

value (NPV) of FNAC were calculated from the data. Conclusions were made and a comparative assessment of our results with local and international studies was made.

RESULTS

A total of 60 cases were included in the study. The ages of the patients ranged from 20 to 70 years. The mean age was 35.7±11.04 years. The male: female ratio was 1:4. The FNAC findings in this series were: benign 44 (77.3%), malignant 8 (13.3%) and suspicious 8 (13.3%). The distribution of various diseases in the solitary thyroid nodules on FNAC is shown in Table I.

FNAC FINDINGS IN THE SOLITARY THYROID NODULES

Type	Disease	No. of cases (n=60)
Benign (n=44)	Adenomatous colloid goitre	29
	Colloid cystic goitre	15
Malignant (n=8)	Papillary carcinoma	5
	Anaplastic carcinoma	2
	Metastatic sq cell carcinoma	1
Suspicious to be Malignant (n=8)	Adenoma	5
	Follicular neoplasms	3

Table-I

The total number of benign and malignant cases as determined on biopsy examination was 47 (78.3%) and 13 (21.7%) respectively. After comparison with biopsy findings, 2 cases of adenomatous colloid goiter were found to be papillary carcinomas. 3 cases of adenoma were proved as such and 2 cases were found to be follicular carcinomas. Out of the three cases of follicular neoplasm, 2 were found to be adenoma and 1 proved to be follicular carcinoma. The biopsy findings are shown in Table II. For the purpose of analysis the suspicious cases were considered as malignant. The comparison of FNAC and biopsy in the solitary thyroid nodule is shown in Table III. The diagnostic value of FNAC in solitary thyroid nodule after comparison with biopsy was calculated at; Accuracy 88%, sensitivity 85%, specificity 90%, positive predictive value 69% and negative predictive value 95%.

DISCUSSION

Thyroid cancer is uncommon, with an estimated incidence in various parts of the world of 0.5 to 10 cases per 100,000 population. It accounts roughly for about 0.5% of all cancers in men and 1.5% of all cancers in

THE FINDINGS OF BIOPSY IN SOLITARY THYROID NODULES

Type	Disease	No. of cases (n=60)
Benign (n=47)	Adenomatous colloid goitre	27
	Colloid cystic goitre	15
	Adenoma	5
Malignant (n=13)	Papillary carcinoma	7
	Fillicular carcinoma	3
	Anaplastic carcinoma	2
	Metastatic sq cell carcinoma	1

Table-II

COMPARISON OF FINE NEEDLE ASPIRATION CYTOLOGY (FNAC) WITH BIOPSY IN THE SOLITARY THYROID NODULE

FNAC		Biopsy	
		Malignant (n=13)	Benign (n=47)
	Malignant/Suspicious* (n=16)	11	5
	Benign (n=44)	2	42

*Suspicious' cases on cytology taken as positive for malignancy

Sensitivity= $11/13 \times 100 = 84.62\%$
 Specificity= $42/47 \times 100 = 89.36\%$
 Positive Predictive Value= $11/16 \times 100 = 68.75\%$
 Negative Predictive Value= $42/44 \times 100 = 95.46\%$

Table-III

women⁸. The most common types of thyroid cancers are differentiated thyroid cancers and follicular and papillary thyroid cancers are the main differentiated thyroid cancers. Papillary carcinoma contributes for 70%, follicular carcinoma for 12% and the follicular variant of the papillary carcinoma for 6% of all the thyroid cancers⁹. The histopathologic distribution of differentiated thyroid cancer is comparable to international literature, as has been reported previously from Pakistan by various authors. In Pakistan, thyroid cancer is responsible for 1.2% cases of all malignant tumors¹⁰.

The primary challenge in the management of a solitary thyroid nodule is to rule out malignancy. Follicular carcinoma and Hurthle cell carcinoma cannot be di-

agnosed by cytology as the diagnosis of malignancy is made by vascular and capsular invasion¹¹⁻¹³. Therefore the cytological diagnoses of adenoma, hyperplastic nodules and follicular neoplasms should be viewed with suspicion. In this study, two cases of adenoma and one follicular neoplasm proved malignant on subsequent histopathological examination. Only two false negative cases occurred in adenomatous colloid goitres and the rest 25 were confirmed benign on histopathological examination. This is in agreement with Jayarm and colleagues who studied 308 cases of solitary thyroid nodules with FNA. The pathological diagnosis was correctly established from aspirates in (95.8%) adenomatous colloid goiters. In the same series follicular adenomas were diagnosed as follicular neoplasms in 11 of 11 patients. However, only 4 of 19 follicular carcinomas were accurately diagnosed using FNA. The false-negative rate for follicular carcinoma varies from 2.4-5.3%¹⁴.

Papillary carcinoma was the most common thyroid malignancy in our study. They are readily diagnosed by FNA cytology. All such cases were correctly identified in our study. Anaplastic thyroid carcinoma is a rare but a very aggressive tumour. It is easily recognized by cytology. Correct identification of this lesion from lymphoma is important because cure may be achieved in the latter case.

A wide range of values for the diagnostic accuracy of FNAC in the diagnosis of solitary thyroid nodules can be found in the literature. Mamoon N et al found a sensitivity of 92.8%, a specificity of 90.1% and accuracy 90.3% for FNAC in the thyroid gland in their study¹⁵. In a similar study conducted by Safirullah and colleagues, in the same institution put these figures at; sensitivity 94.2% and specificity 94%¹⁶. Ghazanfar A and colleagues in their study found the diagnostic accuracy of FNAC at 93%, sensitivity at 90.8% and the specificity at 95.1% in thyroid disease¹³. Other studies from Pakistan have also reported encouraging figures. Sohail Raza and colleagues reported both the sensitivity and specificity of FNAC in solitary thyroid nodules at 100% and recommended the routine use of FNAC in the preoperative evaluation of solitary thyroid nodules.¹⁷ Sial KH, et al reported that FNAC has a high accuracy rate of 82% as a diagnostic modality to differentiate between benign and malignant solitary thyroid nodule¹⁸.

Gharib H in a review of seven series analysis showed a false-negative rate of 1% to 11%, a false-positive rate of 1% to 8%, a sensitivity of 65% to 98%, and a specificity of 72% to 100% for FNA cytology in thyroid lesions.² Bouvet et al, in their study on the role of aspiration cytology in solitary thyroid nodules reported sensitivity, specificity, and the accuracy of FNAC at 93.5%, 75%, and 79.6%, respectively¹⁹. C. Ravetto and colleagues, in a large series including 4069 patients with thyroid lesions reported the sensitivity and specificity of FNAC at 91.8% and 75.5% respectively²⁰. The current international data shows the accuracy of FNAC to be

95%, sensitivity 70-90% and specificity at 80-100% in thyroid gland disease.

CONCLUSION

The results of this study suggest that FNAC is simple and a reliable technique and it is recommended to evaluate preoperatively all the solitary thyroid nodules with the help of this technique. However, keeping in mind the limitations of the technique and the occurrence of false negative cases, open biopsy should confirm the diagnosis where doubt exists.

REFERENCES

- Mazzaferri EL. Management of a solitary thyroid nodule. *N Engl J Med* 1998; 328: 553-8.
- Gharib H, Goellner JR. Fine needle aspiration biopsy of the thyroid: An appraisal. *Ann Intern Med* 1993; 118: 282-9.
- Ridgway EC. Clinical evaluation of solitary thyroid nodules. In: Ridgway EC. ed. *The Thyroid*. 3rd ed. Philadelphia: GB Lippincott 1986: 1377-85.
- Watkinson J C. Diseases of the thyroid and parathyroid glands. In: Gaze M N, Wilson J A, editors. *Stell and Maran's Head and neck surgery*. 4th ed. London: Butterworth/Heinmann 2000: 459-85.
- Lowhagen T, Granberg PO, Lundell G, Skinnari P, Sundblad R, Willems JS. Aspiration biopsy cytology (ABC) in nodules of the thyroid gland suspected to be malignant. *Surg Clin North Am* 1979; 59: 3-18.
- Orell SR. Pitfalls in fine needle aspiration cytology. *Cytopathol* 2003; 14: 173-82.
- Chaturvedi NK. Critical issues in fine needle aspiration (FNA) techniques. *J Ind Acad Clin Med* 2000; 1: 1-4.
- Sherman SI. Thyroid carcinoma. *Lancet* 2003; 361: 501-11.
- Boignon M, Moyer D. Solitary thyroid nodules, separating benign from malignant conditions. *Postgrad Med* 1995; 98: 73-80.
- Shah SH, Muzaffar S, Soomro IN, Hasan SH. Morphological patterns and frequency of thyroid tumors. *J Pak Med Assoc* 1999; 49: 131-3.
- Gharib H. Fine needle aspiration biopsy of thyroid nodules: Advantages, limitations and effect. *Mayo Clin Proc* 1996; 69: 44-9.
- McHenry CR, Rosen IB, Walfish PG, Easter N. Non-diagnostic fine needle aspiration biopsy: a dilemma in management of nodular thyroid disease. *Am Surg* 1993; 59: 415-9.
- Ghazanfar A, Choudhry ZA, Nasir SM, Ahmad W. Correlation of the diagnostic accuracy of FNAC to the clinical and histological diagnosis- A prospective study of 100 cases. *Ann K E Med Coll* 2001; 7: 131-3.
- Jayaram G. Fine needle aspiration cytologic study of the solitary thyroid nodule. Profile of 308 cases with histologic correlation. *Acta Cytol* 1985; 29: 967-73.
- Mamoon N, Mushtaq S, Muzaffar M, Khan A. The use of fine needle aspiration biopsy in the management of thyroid disease. *J Pak Med Assoc* 1997; 47: 255-8.
- Safirullah, Mumtaz N, Khan A. Role of fine needle aspiration cytology (FNAC) in the diagnosis of thyroid swellings. *J Postgrad Med Inst* 2004;18: 196-201.
- Raza S, Saeed Z, Raza H, Ahmed M. FNAC in the management of solitary thyroid nodule. *Professional Med J* 2006; 13(4): 596-603.
- Sial KH, Mangi BA. Efficacy of FNAC in detecting lesions of solitary thyroid nodule. *Pak J Surg* 2003; 19(1): 17-20.
- Bouvet M, Feldman JI, Gill GN, Dillman WH, Nahum AM, Russack V, et al. Surgical management of the thyroid nodule: Patient selection based on the results of fine-needle aspiration cytology. *Laryngoscope* 1992; 102: 1353-6.

CONFLICT OF INTEREST

Authors declare no conflict of interest