



GLUTARIC ACIDEMIA TYPE I: A CASE REPORT FROM PAKISTAN

Noshaba Noor¹✉, Hira Waseem¹

ABSTRACT

INTRODUCTION: Glutaric aciduria type I is a neurometabolic disorder occurring due to deficient activity of glutaryl-CoA dehydrogenase. Multiple neurotoxic metabolites start accumulating in plasma, CSF and urine which are detected by mass spectrometry. Early new-born screening plays an important role in early diagnosis whereas typical radiographic features and metabolic workup supports the diagnosis. Treatment guidelines have been constructed to prevent acute encephalopathic crisis and remove neurotoxic metabolites from plasma to prevent brain damage, the goal of treatment.

CASE PRESENTATION: An eight month old male patient presented with fever, seizures and altered level of consciousness. He was macrocephalic with examination findings suggestive of upper motor neuron lesion. The typical radiologic features suggestive of glutaric aciduria type I were noticed in neuroimaging. Workup for inborn error of metabolism confirmed the same. Early treatment was started keeping a metabolic disease consultant on board. The patient was safely discharged from hospital after stabilization and is well till date.

CONCLUSION: This case is being reported to emphasize the importance of early diagnosis, timely management and adherence to proper treatment in paediatric patients presenting with metabolic crisis. This can help prevent irreversible damage in patients especially in the ones diagnosed as glutaric aciduria type I.

KEYWORDS: Glutaric Aciduria Type I (MeSH); Multiple Acyl Coenzyme A Dehydrogenase Deficiency (MeSH); New Born Screening (Non-MeSH); Inborn error of metabolism (Non-MeSH), Organic aciduria (Non-MeSH), Organic academia (Non-MeSH); Autosomal recessive (Non-MeSH); Neurometabolic disorder (Non-MeSH), Glutaric acidemia (MeSH)

THIS ARTICLE MAY BE CITED AS: Noor N, Waseem H. Glutaric acidemia type I: a case report from Pakistan. *Khyber Med Univ J* 2022;14(1):71-73. <https://doi.org/10.35845/kmu.2022.21984>.

INTRODUCTION

Glutaric acidemia type I (GA-I) is an autosomal recessive neurometabolic disorder resulting from a mutation of a gene located on chromosome 19. It leads to deficient activity of glutaryl-CoA dehydrogenase, a flavoprotein involved in degradation pathway of tryptophan, L-hydroxylysine and lysine.¹ Deficiency of this enzyme leads to accretion of glutaric acid, glutaric acid and 3-hydroxyglutaric acid in urine, cerebrospinal fluid and plasma by gas chromatography/mass spectrometry.^{2,3}

A six year study of new born screening in Saudi Arabia with a coverage rate of 100% showed very long-chain acyl CoA dehydrogenase deficiency and glutaric

aciduria type one had an incidence of 1:18877 each.⁴ It is a treatable disorder if diagnosed earlier with NBS. A Turkish study demonstrated severely-affected infants due to late diagnosis.⁵ Macrocephaly is the most characteristic and earliest presentation in infants.

Developmental regression and severe dystonic-dyskinetic disorder effect around 90% patients.⁶ Brain cognition is generally preserved in patients with striatal degeneration but patients with dystonias predominantly show motor speed impairment.⁷ Treatment of glutaric aciduria includes protein and fat limitation in the diet, avoiding prolonged fasting, high-dose riboflavin (100-300 mg daily), carnitine supplementation (50-100 mg/kg daily in three divided

1: National Institute of Child Health, Karachi, Pakistan.

Email ✉: drnoshabanoor@gmail.com

Contact #: +92-324-2635034

Date Submitted: September 05, 2021

Date Revised: February 11, 2022

Date Accepted: February 12, 2022

doses) and coenzyme Q₁₀ supplements (60-240 mg daily in two divided doses). The appropriate treatment guidelines can help prevent acute encephalopathic crisis and striatal damage.⁸

We report a case of glutaric aciduria type I, an eight years old male child who presented with fever, seizures and altered level of consciousness.

CASE DESCRIPTION

Patient Information

Our patient was an eight-month-old male who was referred from a local hospital with clinical suspicion of meningoencephalitis with normal findings of cerebrospinal fluid analysis.

Patient had three days history of high grade fever, convulsions involving left side of body followed by a short period of post-ictal drowsiness. Fever was high grade, acute in onset, intermittent and not associated with any rigors or chills. Patient had fits involving the left side of body that lasted for around 2-3 minutes, unrolling of eyes, frothing of saliva and fecal incontinence. The patient had impaired conscious level for around twenty minutes. There was no previous history of hospital admissions, no associated history of loose motions, vomiting, reluctance to feed, cough, respiratory distress. No previous history of seizures, no history of blood transfusion and no significant surgical history. He was born at term via caesarean section due to oligohydramnios according to mother told by gynecologist in last trimester, immediate cry, no NICU admission. Child has been vaccinated till date, no documentations available though. He was breastfed exclusively until four months of age, weaning started at 4th

month of age with semisolid diet. Developmentally, he achieved social smile at two months of age with neck holding at three months and started sitting with support at seven months. There is consanguinity among parents. He is the second alive baby. Elder sibling is three years old active and healthy female, no history of miscarriage or sibling death. Family history was significant for two maternal and paternal cousin deaths at three years and ten months of age, respectively, with complains of fever and convulsions.

No documentation of their cause of death was available. Father employer in the local office with overall low socioeconomic status. They take boiled water, do not have any pets at home with overall poor sanitary conditions.

PHYSICAL EXAMINATION

Examination findings showed weight and length less than the third centile for age and fronto-occipital circumference lying at 90th centile for age suggestive of macrocephaly (Figure 1). CNS findings showed increased tone in all four limbs with brisk reflexes, plantars bilaterally upgoing.

Anterior fontanel was open 1 × 1 cm and full. Examination findings were consistent with upper motor neuron lesion. Rest of the examination was unremarkable.

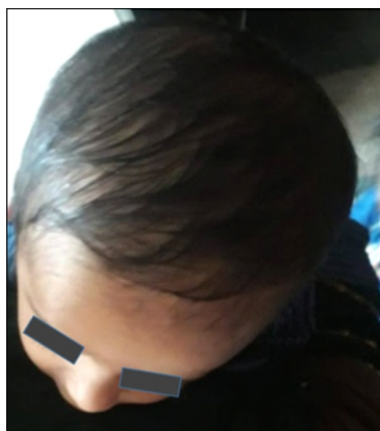

Figure 1: Showing macrocephaly

DIAGNOSTIC ASSESSMENT

Patients was initially managed as meningoencephalitis. We ordered neuroimaging, which reported bilateral widened opercula, frontoparietal atrophy and dilated sylvian fissures showing “bat wing configuration”,

(Figure 2) dilatation of ventricular system along with widened extra axial CSF spaces predominantly anterior to temporal poles. Keeping a significant family history of cousin deaths in view, we considered working up for the differential of inborn error of metabolism. Plasma lactic acid was sent which was borderline elevated 2.1 (05-01.6 mmol) & plasma ammonia was elevated as well 99 (<68 ug/dl). Arterial blood gases showed severe metabolic acidosis with pH=7.17, pCO₂=23.3,

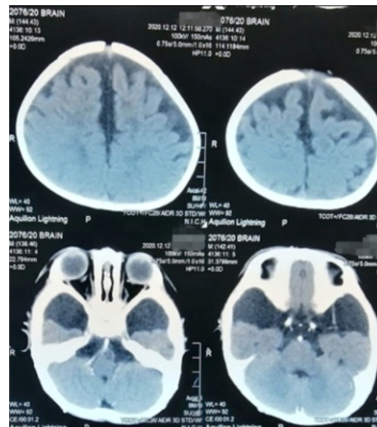


Figure 2: Multiple sections of CT brain demonstrating frontoparietal atrophy, dilated sylvian fissures, dilated opercula and typical bat-wing like appearance

pO₂ = 165, HCO₃ = 10.9, SaO₂ = 99.7

Plasma amino acid levels were sent which showed less than normal levels of alanine, cysteine, isoleucine, leucine, phenylalanine and histidine but the changes were nonspecific and urine gas chromatography/mass spectrometry analysis was advised.

It showed marked excretion of Glutaric acid, 3-hydroxyglutaric acid and along with it, a moderate peak of glutaconic acid were identified. Profile was suggestive of glutaric aciduria type one due to glutaryl-CoA dehydrogenase deficiency.

THERAPEUTIC INTERVENTIONS

Metabolic disease consultant was taken on board. L-Carnitine oral suspension was started with dosage of 150 mg/kg/day in three divided doses. Dietary modifications were done and diet was tailored to ensure the child receives a lysine- and tryptophan-restricted diet. Diet chart was provided to attendants.

Pharmacotherapy with riboflavin and carnitine was ensured to arrest the neurological deterioration in the patient.

FOLLOW UP AND OUTCOME

Counselling of family was done regarding sending genetic workup for the disease but they refused to send the genetic panel due to financial constraints. At present, the patient is eleven months old, has no neck holding and is unable to sit without support.

DISCUSSION

Diagnosing glutaric aciduria timely is crucial just like other inborn errors of metabolism as timely treatment prevents patients from irreversible neurological damage.

In Pakistan, till date there doesn't exist any national new-born screening program for inborn errors of metabolism nor the incidence of glutaric aciduria has ever been studied.

Without treatment, severe and life-threatening symptoms can develop, including seizures or falling into a coma. Overall impact of GA type one will depend on the amount of brain damage but an acute brain damaging episodes before age of six years puts the child at risk of medical problems throughout life and their life expectancy is shortened as well. At ten years of age, survival rate is 90% and at thirty-five years it is 44%.⁹

Glutaric aciduria is considered one of the organic acidurias lacking typical metabolic derangements (hypoglycaemia, metabolic acidosis or hyperammonaemia) seen in inherited metabolic disorders presenting with metabolic decompensation.¹⁰

Thus, correlating thorough history and examination should alert the physician to screen patients for this disorder. As the revised guidelines for emergency treatment and maintenance therapy have shown to bring a positive outcome of this treatable disorder. In a resource-limited country like Pakistan, screening the index patient's relatives to identify asymptomatic patients and carriers can contribute to efforts made to achieve favorable outcomes.

REFERENCES

- Ribeiro JV, Lucas TG, Bross P, Gomes CM, Henriques BJ. Potential complementation effects of two disease-associated mutations in tetrameric glutaryl-CoA dehydrogenase is due to intersubunit stability-activity counterbalance. *Biochim Biophys Acta Proteins Proteom* 2020;1868(1):140269. <https://doi.org/10.1016/j.bbapap.2019.140269>
- Schor DS, Verhoeven NM, Struys EA, ten Brink HJ, Jakobs C. Quantification of 3-hydroxyglutaric acid in urine, plasma, cerebrospinal fluid and amniotic fluid by stable-isotope dilution-negative chemical ionization gas chromatography-mass spectrometry. *J Chromatogr B Analyt Technol Biomed Life Sci* 2002;780(1):199-204. [https://doi.org/10.1016/s1570-0232\(02\)00406-3](https://doi.org/10.1016/s1570-0232(02)00406-3)
- Bouchereau J, Schiff M. Inherited Disorders of Lysine Metabolism: A Review. *J Nutr* 2020;150(Suppl 1):2556S-60S. <https://doi.org/10.1093/jn/nxaa112>
- Mohamed S, Elsheikh W, Al-Aqeel AI, Alhashem AM, Alodaib A, Alahaideb L, et al. The incidence of newborn screening disorders among 56632 infants in Central Saudi Arabia. A 6-year study. *Saudi Med J* 2020;41(7):703-8. <https://doi.org/10.15537/smj.2020.7.25147>
- Kilavuz S, Bulut D. The outcome of 41 Late-Diagnosed Turkish GA-I Patients: A Candidate for the Turkish NBS. *Neuropediatrics* 2021;52(5):358-69. <https://doi.org/10.1055/s-0040-1722691>
- Afroze B, Yunus ZM. Glutaric aciduria type I - importance of early diagnosis and treatment. *J Pak Med Assoc* 2014;64(5):593-5.
- Boy N, Heringer J, Haegge G, Glahn EM, Hoffmann GF, Garbade SF, et al. A cross-sectional controlled developmental study of neuropsychological functions in patients with glutaric aciduria type I. *Orphanet J Rare Dis* 2015;10:163. <https://doi.org/10.1186/s13023-015-0379-6>
- Prasun P. Multiple Acyl-CoA Dehydrogenase Deficiency. In: Adam MP, Ardinger HH, Pagon RA, Wallace SE, Bean LJH, Stephens K, et al., editors. *GeneReviews®* [Internet]. 1993-2020, University of Washington, Seattle, USA.
- Kyllerman M, Skjeldal O, Christensen E, Hagberg G, Holme E, Lönnquist T, et al. Long-term follow-up, neurological outcome, and survival rate in 28 Nordic patients with glutaric aciduria type I. *Eur J Paediatr Neurol* 2004;8(3):121-9. <https://doi.org/10.1016/j.ejpn.2003.12.007>
- Guerrero RB, Salazar D, Tanpaiboon P. Laboratory diagnostic approaches in metabolic disorders. *Ann Transl Med* 2018;6(24):470. <https://doi.org/10.21037/atm.2018.11.05>

AUTHOR'S CONTRIBUTION

Following authors have made substantial contributions to the manuscript as under:

NN: Identification, diagnosis & management of the case, drafting the manuscript, approval of the final version to be published

HW: Diagnosis & management of the case, critical review, approval of the final version to be published

Authors agree to be accountable for all aspects of the work in ensuring that questions related to the accuracy or integrity of any part of the work are appropriately investigated and resolved.

CONFLICT OF INTEREST

Authors declared no conflict of interest

GRANT SUPPORT AND FINANCIAL DISCLOSURE

Authors declared no specific grant for this research from any funding agency in the public, commercial or not-for-profit sectors

DATA SHARING STATEMENT

The data that support the findings of this study are available from the corresponding author upon reasonable request



This is an Open Access article distributed under the terms of the Creative Commons Attribution-Non Commercial 2.0 Generic License.

KMUJ web address: www.kmuj.kmu.edu.pk

Email address: kmuj@kmu.edu.pk