

FAMILIAL CAMPTODACTYLY COXA VARA PERICARDITIS SYNDROME (CACP): Case Report

by Shahzadi Sumbal

Submission date: 21-Dec-2017 10:49AM (UTC+0500)

Submission ID: 898677764

File name: 18072-71429-1-RV.docx (284.59K)

Word count: 889

Character count: 5367

FAMILIAL CAMPTODACTYLY ² COXA VARA PERICARDITIS SYNDROME (CACP)

ABSTRACT

The camptodactyly-arthropathy-coxa vara-pericarditis syndrome (CACP) ⁷ is a rare autosomal recessive disease characterized by congenital or early-onset camptodactyly, childhood-onset noninflammatory arthropathy associated with synovial hyperplasia, constrictive pericarditis and coxa vera. This rare disease is caused by mutations in *PRG4 Gene* which encodes for lubricin, a protein present in synovial fluid responsible for lubrication.

The case we are reporting is of 9 and a half years old boy who presented to us in pediatric Out Patient Department with early onset camptodactyly and noninflammatory arthropathy. Synovial biopsy shows synovial hyperplasia with numerous CD68 positive multinucleated giant cells. He was discharged and physiotherapy was advised with regular follow ups.

³ KEY WORDS

camptodactyly-arthropathy-coxa vara-pericarditis syndrome (CACP); PRG4 Gene; Lubricin; Joint Diseases; Arthropathy; Osteoarthritis; Pericarditis; Synovial Membrane;

CASE REPORT

¹ A 9.5 year old boy was admitted due to deformity of fingers and toes in May, 2015. In May 2013 he was diagnosed as a case of pauciarticular JIA for which methotrexate and folic acid started. He presented to our OPD due to bilateral knee joint swelling and deformity of fingers which was not responding to treatment. Camptodactyly of thumb was observed soon after birth by the mother

which was progressive. We decided to admit the patient for workup and revise the diagnosis. General physical examination showed a BP 100/70mmHg, pulse rate 88/minute, temperature 98.4F and RR 26/minute. Swelling of B/L knee joint observed. There was no evidence of fever, rash and lymphadenopathy. Another younger brother has also started to develop same complaints.

Laboratory findings revealed Hb 11.4g/dl TLC 9.9 with 40.5% neutrophils and 45.6% lymphocytes Platelet 198,000. ESR 9mmHg. CRP negative. RA factor and ANA factor negative. Serum electrolytes Na 141mmol/L K 3.9mmol/L Ca 1.2mmol/L. Urea 27mg/dl and creatinine 0.56mg/dl. Chest X-ray was normal. Plain radiograph of hands showed flexion deformity of PIP joints of fingers and thumb of both hands (Fig.1).

MRI knee joint show thin rim like enhancement of fluid filled bursa (Fig.2). Synovial biopsy done and report shows synovial proliferation with numerous CD 68 positive multinucleated giant cells consistent with CACP. He was diagnosed to have CACP. Orthopedic consultation taken for splint application and z-plasty after the diagnosis. Echocardiography done which was normal. He was discharged on physiotherapy and advised regular follow up to check for development of pericarditis.

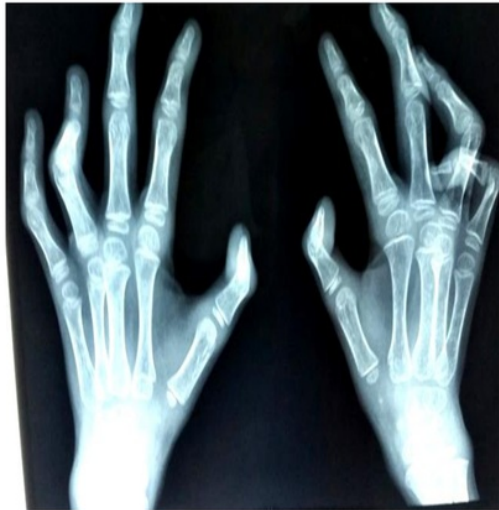

Fig.1: X-ray hands showing B/L camptodactyly

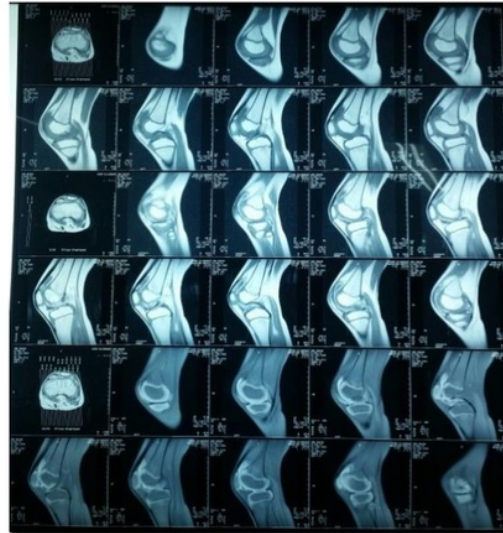


Fig.2: MRI Knee joint showing rim like enhancement of filled bursa

DISCUSSION

³ The camptodactyly-arthropathy-coxa vara-pericarditis syndrome (CACP) is a rare autosomal recessive disorder caused by mutation in PRG4 gene.⁶ 15 mutations in PRG4 gene responsible for causing CACP have been listed in Human Genome Mutation Database (www.hgmd.cf.ac.uk).^[1] PRG4 gene encodes for Lubricin, a large protein present in large amount in synovial fluid of joints. It is secreted by joint fibroblasts and chondrocytes and serves as lubricant for boundary and protects articular cartilage from friction induced injury. Lubricin is found in many other parts of body such as on tendon surface, pleural and pericardial cavities, liver, kidney and muscles. In pleural and pericardial cavities lubricin has likely ⁵ antiadhesive function. In humans, absence of this important protein is mainly responsible for camptodactyly-arthropathy-coxa vara-pericarditis syndrome (CACP)^[2]. Consequently lack of lubricin will lead to synovial hyperplasia which can have deleterious effects on joint cartilage by inhibiting nutrient and waste exchange. Tissue remodeling and tendon sheath calcification may result into camptodactyly.^[3]

Clinically child with CACP presents with non traumatic fixed flexion deformity of proximal interphalangeal joint of fingers (camptodactyly), which may be congenital or acquired and usually bilateral resulting into contracture. Usually child complains of swelling, pain and limited range of motion in large joints such as elbows, hip, knee and ankle (Arthropathy). Non inflammatory constrictive

pericarditis is present in upto 30 percent cases of CACP published so far and may be mild in nature and is self limiting ^[4]. Coxa vara ,where the angle between shaft and head of femur is decreased to less than 120 degrees, resulting in shortening of affected limb is present in 50-90 % of the cases, progresses gradually over time ^[3].

Diagnosing patients with CACP syndrome is very important as they mostly present with sign and symptoms which mimic common rheumatic conditions such as juvenile idiopathic arthritis (JIA) and are treated for these, as it was in our case, being treated with methotrexate ^[1, 5]. Children with CACP have swollen joints that are cool, refractory to anti-inflammatory therapy. Synovial fluid analysis is negative for inflammation. Histopathological findings of synovial tissue shows marked synovial hyperplasia with no evidence of inflammation while hyperplasia of synovium is associated with chronic inflammation in case of rheumatoid arthritis. MRI is useful in differentiating CACP from other childhood connective tissue disorders such as JIA .MRI of the involved joint will show rim like enhancement of fluid filled bursa on T1 weighted image before and after contrast enhancement ^[4]. Echocardiography can be done for diagnosis of pericarditis.^[6]

Overall prognosis of CACP syndrome is good and most of the patients do not encounter serious problems.

Camptodactyly can be managed conservatively by splinting and physiotherapy but sometimes tenolysis or synovectomy may be necessary. Various new techniques have been tried for synovectomy but without any satisfactory improvement in the treatment of CACP. Al-Mayouf SM et al. tried Yttrium-90 radiosynovectomy in patients of CACP syndrome but they concluded no beneficial therapeutic effect of their treatment of arthropathy of CACP syndrome.^[5] pericarditis is usually mild and self limiting but in life threatening cases pericardiocentesis may be necessary.

REFERENCES:

FAMILIAL CAMPTODACTYLY COXA VARA PERICARDITIS SYNDROME (CACP): Case Report

ORIGINALITY REPORT

16%

SIMILARITY INDEX

11%

INTERNET SOURCES

14%

PUBLICATIONS

%

STUDENT PAPERS

PRIMARY SOURCES

- 1 jkms.kams.or.kr 5%
Internet Source
- 2 diseaseinfosearch.org 4%
Internet Source
- 3 Anas M. Alazami. "Novel PRG4 mutations underlie CACP in Saudi families", Human Mutation, 02/2006 3%
Publication
- 4 Byung-Ryul Choi. "Camptodactyly, Arthropathy, Coxa vara, Pericarditis (CACP) Syndrome: A Case Report", Journal of Korean Medical Science, 2004 2%
Publication
- 5 Bechtold, Till E., Cheri Saunders, Rebekah S. Decker, Hyo-Bin Um, Naiga Cottingham, Imad Salhab, Naito Kurio, Paul C. Billings, Maurizio Pacifici, Hyun-Duck Nah, and Eiki Koyama. "Osteophyte formation and matrix mineralization in a TMJ osteoarthritis mouse 1%

model are associated with ectopic hedgehog signaling", Matrix Biology, 2016.

Publication

6

www.jsi-medisys.de

Internet Source

1%

7

Carames, B.. "P195 INHIBITION OF MITOGEN KINASE PHOSPHATASE 1 (MKP-1) POTENCIATES CELL DEATH INDUCED BY TUMOR NECROSIS FACTOR @a (TNF@a) BUT NOT BY INTERLEUKIN 1 @b (IL-1@b) IN NORMAL HUMAN ARTICULAR CHONDROCYTES", Osteoarthritis and Cartilage, 2006

Publication

1%

Exclude quotes On

Exclude matches Off

Exclude bibliography On