

# Helical stairs: An unusual peroneal neuropathy etiology; A case report

*by* Atif Ahmed Khan

---

|                |                                 |                 |      |
|----------------|---------------------------------|-----------------|------|
| FILE           | 17658-68911-1-RV.DOCX (140.03K) |                 |      |
| TIME SUBMITTED | 22-MAY-2017 01:23PM             | WORD COUNT      | 1627 |
| SUBMISSION ID  | 817310997                       | CHARACTER COUNT | 9291 |

## **Helical stairs: An unusual peroneal neuropathy etiology; A case report**

**Dr Atif Ahmed Khan**

MBBS, Dip PM&R, FCPS(PM&R)

Head of Department Physical Medicine and Rehabilitation

Combined Military Hospital, Kohat, Pakistan.

Phone: 03315561888

E-mail. [atifafirm@gmail.com](mailto:atifafirm@gmail.com)

Corresponding Author:

**Dr Atif Ahmed Khan**

MBBS, Dip PM&R, FCPS (PM&R)

Head of Department Physical Medicine and Rehabilitation

Combined Military Hospital, Kohat, Pakistan.

Phone: 03315561888

E-mail. [atifafirm@gmail.com](mailto:atifafirm@gmail.com)

## Abstract:

Peroneal neuropathy is a common focal compression neuropathy presenting with foot drop. Wide variety of conditions results in peroneal neuropathy around the knee which includes habitual and occupational related, trauma related, post-surgical or sports related. We present here a case where climbing helical stairs caused clinically and electrodiagnostically proven peroneal neuropathy around knee in a 53yr old male, which was a unique etiology of peroneal neuropathy. The patient underwent twelve week of comprehensive rehabilitation following which he showed substantial improvement in functional activities.

**MeSH Keyword:** Peroneal Neuropathies, Electromyography, Neural Conduction

## Introduction:

<sup>6</sup> Fibular (peroneal) neuropathy is the commonest mononeuropathy of lower limb.<sup>1</sup> Patients presents with difficulty walking, frequent stumble and foot drop as a result of weakness of ankle dorsiflexors. Such condition is also encountered in several other localized disorders like sciatic neuropathy, lumbosacral plexopathy, or lumbar 5 radiculopathy.<sup>2</sup> Generalized disorder like amyotrophic lateral sclerosis and hereditary polyneuropathy can also present with symptoms and, thus, should be investigated to identify the disorder. Acute trauma, surgical intervention, habitual and occupational related condition leading to compression and stretch are the common mechanism causing peroneal neuropathy.<sup>3</sup> Area around the Head of fibula is the most frequently involved site of injury to the fibular nerve.<sup>4</sup> electrodiagnostic studies are used to localize the site of the nerve injury, determine the severity of the damage and to rule out conditions mimicking peroneal neuropathy.<sup>8</sup> The purpose of our case report is to highlight a varied etiology of peroneal neuropathy. Ethical

permission from hospital and permission from the patient was obtained before writing the manuscript.

#### **Case Report:**

A 53<sup>9</sup> year old man with left foot drop was referred in October 2016 by a physician to department of physical medicine and rehabilitation of our hospital for electrodiagnostic studies. Patient had developed painless weakness of left foot 3 months back resulting gradually in foot drop and difficulty walking. Patient had a history of intragluteal injection 5 months back for high grade fever. Patient had no history of trauma, backache, viral infections. On further enquiry, the patient told that three months back he was involved in construction of the upper story of his house during which he use to take bricks and cement in small quantity at a time to the upper story using iron helical stairs. The stairs are made in a tight space with sharp angles. Daily he used to make more the fifty trips up and down the helical stairs and this continues for more the two weeks. During last few days of that period patient felt difficulty in climbing stairs which he felt was due to fatigue so he pulled himself out of that project. He reported to local general practitioner who has related the weakness to intragluteal injection and treated him with multi vitamins and non-steroidal anti-inflammatory drugs but patient remained symptomatic. On examination, there was no sign of trauma, no scar on the left leg. Muscle bulk of peroneus, tibialis anterior, extensor hallucis longus muscle was normal. Active dorsiflexion of the left foot at tibiotalar joint was week while plantarflexion at tibiotalar, eversion/ inversion and adduction/abduction at subtalar and other small joint complex was normal. Passive range of motion at all joints of foot was full and painless. On medical research council muscle power testing, power in peroneal muscle and posterior leg compartment muscles, hamstring, quadriceps and glutii was 5/5 while power in tibialis anterior and extensor hallucis longus was 1/5. Sensation impairment was found only in the first<sup>2</sup> dorsal web space on the left foot. Deep tendon reflexes were normal and plantars were down going. X-ray and MRI lumbo-sacral spine was

normal. Musculo-skeletal ultrasound was done around fibular head showing hypertrophy of proximal portion of peroneal muscles. Electrodiagnostic studies were done by an expert in electrodiagnostic studies showing prolong latency, low compound muscle action potential (CMAP) amplitude of left peroneal nerve, substantial decline in CMAP amplitude found across the fibular head by stimulating below and above head of fibula hence showing focal demyelination.(Figure 1) Electromyography was done using concentric needle electrode showing secondary axonal changes in tibialis anterior and extensor hallucis longus muscle while peronei muscles and short head of bicep femoris were normal. Based on history, examination and electrodiagnostic finding, patient was diagnosed as a case of entrapment neuropathy of deep peroneal nerve in the region of proximal fibula resulting from repeated use of helical stairs. A comprehensive rehabilitation plan was carried out which included strengthening exercises and electrical stimulation (EMS) of ankle dorsiflexors, provision of ankle-foot orthosis, gait training, activity modification and medications like membrane stabilizers. After undergoing twelve week of comprehensive rehabilitation power in tibialis anterior and extensor hallucis has improved from initial 1/5 to 4/5 on medical research council muscle power testing. Evidence of recovery was also found on repeat electrodiagnostic studies conducted after six months of the start of therapy. (Figure 2)

#### **Discussion:**

Peroneal neuropathy is identified as the third most frequent focal compression neuropathy following median and ulnar nerve with foot drop as a presenting feature.<sup>5</sup> There are wide variety of conditions that results in peroneal neuropathy around the knee ranging from habitual and occupational related( prolong bed rest, habitual cross leg sitting, prolong squatting, strawberry pickers, prolong kneeling, dieting), trauma related( blunt trauma to knee, lacerations, knee dislocations), post-surgical(arthroplasty, arthroscopy, fracture management, casting, ganglion, bariatric surgery) or sports related( skiing, football).<sup>2,6</sup> In our case repeated climbing of helical stairs resulted in neuropathy of deep fibular nerve which is

a first time encountered cause of deep peroneal neuropathy and not reported so far in the literature.

The <sup>2</sup>anatomy of common peroneal nerve is such that it passes superficial over lateral fibula located 2 <sup>7</sup>cm distal to the head of fibula and then enter anterior leg compartment. At this level <sup>1</sup>it divides into deep and superficial branches. It is at the level of fibular head where most of compression neuropathy of peroneal nerve occurs.<sup>4-6</sup> Studies have shown that abnormalities are reported more in <sup>3</sup>muscles innervated by the deep peroneal nerve as compared to superficial in <sup>3</sup>cases of peroneal neuropathy at the fibular head which is consistent with our patient where both clinical and electro diagnostic abnormalities were noted only in deep peroneal innervated muscles which can be explained by intraneural topography <sup>2</sup>of the common peroneal nerve at <sup>1</sup>fibular head showing the fascicles of the deep fibular nerve placed anteriorly and, thus, are more sensitive to pressure or stretch.<sup>7,1</sup> Repeated climbing up and down the tight turns in the helical stairs may have caused compression of deep peroneal fibers compression against fibula. As the patient was climbing in anticlock wise direction and left leg was the one that was on the inner side hence had to encounter the maximum sharp angles in helical stairs which may explain why only left deep peroneal nerve is affected rather than both deep peroneal nerves.

In cases of suspected peroneal neuropathy, <sup>1</sup>motor and sensory nerve fibers of the peroneal nerve and its branches should be evaluated using nerve conduction studies. Electromyographic study of tibialis anterior muscle should also be carried out which is the most likely muscle to be involved along with <sup>1</sup>at least one muscle innervated by the superficial fibular nerve, the short head of the biceps femoris, and at least one muscle <sup>1</sup>having nerve supply from tibial nerve distal to the knee.<sup>8</sup> In addition to documenting fibular nerve abnormalities and the level of the injury, electrodiagnostic studies also help in prognosis of recovery of nerve function.<sup>8</sup>

Peroneal neuropathy can be managed and functional status can be improved using comprehensive rehabilitation which include use therapeutic exercises, physical modalities, orthotic supports, assistive devices and medications.<sup>9</sup> Our patient showed significant functional improvement after carrying out twelve week of comprehensive rehabilitation. This case demonstrates a unique <sup>5</sup> etiologic cause of sudden drop foot and signifies the importance of electrodiagnostic studies in diagnosing cases of foot drop and effectiveness of comprehensive rehabilitation in management of peroneal neuropathy.



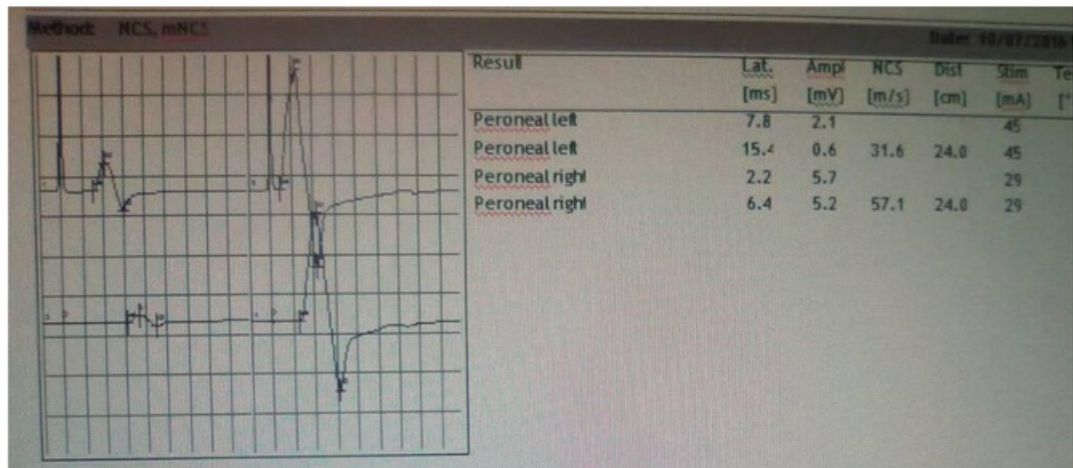


Fig 1: Initial Nerve conduction studies showing left peroneal abnormality

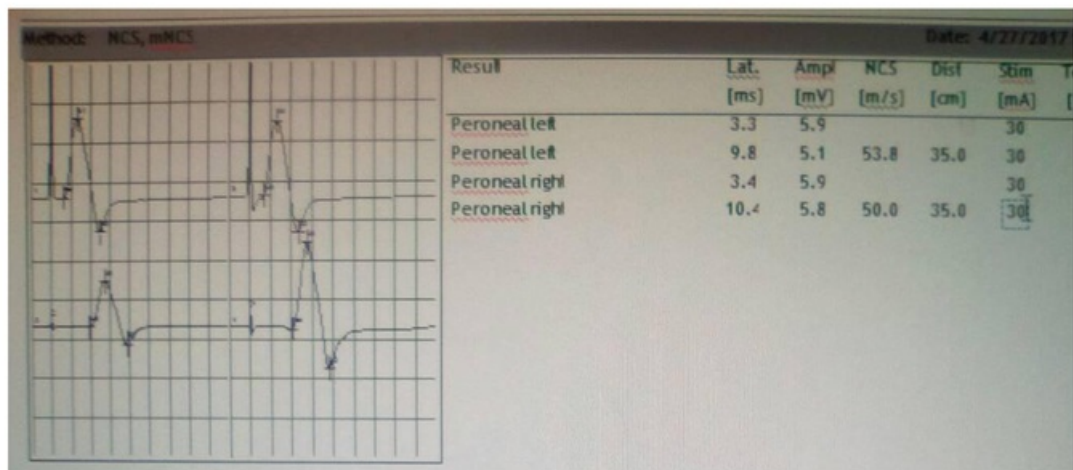


Fig 2: Nerve conduction studies after six months showing evidence of recovery in left peroneal nerve



## References:

1. Eleftheriou KI, Beri S, Alavi A, Tennant S. Deep peroneal nerve palsy during growth spurt: a case report. *Eur J Pediatr* 2013;173(12):1603–5.
2. Stewart JD. Foot drop: where, why and what to do? *Pract Neurol* 2008;8(3):158–69.
3. Koller RL, Blank NK, Berry H RP, Garland H MD, Staal A deWeerd CWL, Stack RE BAMC, et al. Strawberry Pickers' Palsy. *Arch Neurol*. 1980;37(5):320–320.
4. Marciniak C. Fibular (Peroneal) Neuropathy. Electrodiagnostic Features and Clinical Correlates. Vol. 24, *Physical Medicine and Rehabilitation Clinics of North America*. 2013. p. 121–37.
5. Yilmaz E, Karakurt L, Serin E, Güzel H. Peroneal nerve palsy due to rare reasons: a report of three cases. *Acta Orthop Traumatol Turc* 2004;38(1):75–8.
6. Rubin DI, Nottmeier E, Blasser KE, Peterson JJ, Kennelly K. Acute onset of deep peroneal neuropathy during a golf game resulting from a ganglion cyst. *J Clin Neuromuscul Dis* 2004;6(2):49–53.
7. Erdil M, Ozkan K, Ozkan FU, Bilsel K, Turkmen I, Senol S, et al. A rare cause of deep peroneal nerve palsy due to compression of synovial cyst - Case report. *Int J Surg Case Rep* 2013;4(5):515–7.
8. Schulze J, Troeger H. [Fibular nerve compression due to an unusual cause. A case report. *Handchir Mikrochir Plast Chir* 2004;36(1):25–8.
9. Yang LJS, Gala VC, McGillicuddy JE. Superficial peroneal nerve syndrome: an unusual nerve entrapment. *J Neurosurg* 2006;104(5):820–3.

# Helical stairs: An unusual peroneal neuropathy etiology; A case report

## ORIGINALITY REPORT

|                  |                  |              |                |
|------------------|------------------|--------------|----------------|
| 12%              | 8%               | 9%           | %              |
| SIMILARITY INDEX | INTERNET SOURCES | PUBLICATIONS | STUDENT PAPERS |

## PRIMARY SOURCES

|   |   |    |
|---|---|----|
| 1 | depts.washington.edu<br>Internet Source   | 6% |
| 2 | Peripheral Nerve Entrapments, 2016.<br>Publication  | 1% |
| 3 | Preston, David C., and Barbara E. Shapiro.<br>"Peroneal Neuropathy", Electromyography<br>and Neuromuscular Disorders, 2013.<br>Publication  | 1% |
| 4 | Evanthia Mitsiokapa, Andreas F. Mavrogenis,<br>Dionysis Drakopoulos, Cyril Mauffrey, Marius<br>Scarlat. "Peroneal nerve palsy after ankle<br>sprain: an update", European Journal of<br>Orthopaedic Surgery & Traumatology, 2016<br>Publication | 1% |
| 5 | file.scirp.org<br>Internet Source   | 1% |
| 6 | www.jultrasoundmed.org<br>Internet Source   | 1% |
| 7 | MARK HOFFMAN. "Brief Technical Note:<br>SIMULTANEOUS HOFFMANN REFLEX  | 1% |

MEASUREMENTS IN MULTIPLE MUSCLES  
AROUND THE ANKLE", International Journal  
of Neuroscience, 1/1/2003

Publication

8

[www.ncbi.nlm.nih.gov](http://www.ncbi.nlm.nih.gov)

Internet Source

1 %

9

Grant, T. H., I. M. Omar, G. A. Dumanian, C.  
B. Pomeranz, and V. A. Lewis. "Sonographic  
Evaluation of Common Peroneal Neuropathy  
in Patients With Foot Drop", Journal of  
Ultrasound in Medicine, 2015.

Publication

<1 %

EXCLUDE QUOTES    ON  
EXCLUDE            ON  
BIBLIOGRAPHY

EXCLUDE MATCHES    OFF

# Helical stairs: An unusual peroneal neuropathy etiology; A case report

GRADEMARK REPORT

FINAL GRADE

/0

GENERAL COMMENTS

Instructor

PAGE 1

PAGE 2

PAGE 3

PAGE 4

PAGE 5

PAGE 6

PAGE 7

PAGE 8