

# ASSOCIATION OF RHEUMATOID ARTHRITIS WITH PIGMENTED VILLO NODULAR SYNOVITIS OF KNEE: A CASE REPORT

Sahibzada Nasir Mansoor<sup>1✉</sup>, Farooq Azam Rathore<sup>2</sup>

✉ Department of Rehabilitation Medicine, Combined Military Hospital, Pano Aqil, Sind Pakistan  
Email: drnasirmansoor@gmail.com

<sup>2</sup> Consultant and Head of Department of Rehabilitation Medicine, PNS Shifa Hospital, Karachi, Assistant Professor, Bahria University Medical and Dental College, Karachi, Pakistan

Date Submitted: January 20, 2016

Date Revised: May 07, 2016

Date Accepted: May 08, 2016

## ABSTRACT

A twenty-one year old male presented to orthopedic surgeon, with severe pain and swelling in right knee joint. He was diagnosed as a case of Pigmented Villonodular (PVN) on MRI and synovectomy was done. PVN was also confirmed by post-operative histopathology report. He reported for post-surgical knee stiffness and pain at Rehabilitation medicine department. His past history revealed seropositive RA for the past two years with poor compliance to medication. The musculoskeletal examination revealed changes in small joints of hands. He was started with tablet methotrexate 7.5 mg weekly along with physical therapy and anti inflammatory medication. The patient gradually improved achieving normal knee range and reduced clinical symptoms of RA within next 03 months.

PVN affects the knee joints most of the times. Its exact etiology is unknown. PVN is reported to have an association with Systemic Lupus Erythematosus. Its association with rheumatoid arthritis (RA) is reported only once in literature and require further research.

**Key words:** Synovitis; Pigmented Villonodular (MeSH), Arthritis; Rheumatoid (MeSH), Synovectomy (Non-MeSH), Inflammatory arthritis (MeSH), Pakistan (MeSH).

**THIS ARTICLE MAY BE CITED AS:** Mansoor SN, Rathore FA. Association of Rheumatoid arthritis with Pigmented Villonodular synovitis of knee: A case report. *Khyber Med Univ J* 2016; 8(2): 95-97.

## INTRODUCTION

Pigmented villo nodular synovitis (PVNS) affects synovium and tendon sheaths. It is a benign condition. It has a characteristic synovial hyperplasia along with tumor like growth with dense deposits of hemosiderin.<sup>1</sup> It is considered non inflammatory disease but secondary inflammation may occur.<sup>2</sup> Its etiology is unknown but it has been associated with lipid metabolism, tumor genesis, repeated intra articular hemorrhage, and vascular anomalies of the synovium.<sup>3</sup> The disease is characteristically mono articular. It mostly affects the knee. It also affects the hip, ankle, fingers and shoulder joints causing disability due to pain

and can cause damage to cartilage and bone. The male to female ratio is equal. It has two types diffuse and nodular, the later being more common. The common symptoms are swelling, pain, stiffness and aspiration of blood stained fluid. It is treated by synovectomy but relapse can occur in 16-48% cases.<sup>4</sup> It has a fibro cellular nature and is considered benign. It usually affects young adults but most commonly in the 2nd and third decade of life. Annual incidence has been reported between 2-2.5 per million population and 1 % of all rheumatological joint pain presentations.<sup>4</sup>

Rheumatoid arthritis (RA) is a relatively common inflammatory joint disease

with possible autoimmune etiology. The male to female ratio is 3:7. It affect mainly the synovial joints along with extra articular manifestations. It leads to inflammatory arthritis and pannus formation in the affected joints causing pain, stiffness and disability. In advance cases it can lead to joint destruction and deformities.

An extensive literature search on Medline and Google scholar revealed only one similar case report from China. We present a case of RA developing PVNS in his right knee.

## CASE DESCRIPTION

A twenty one year old male, underwent open synovectomy for PVNS. He presented to the rehabilitation clinic with stiffness, pain and swelling of the right knee. (Fig 1) and there was no to conservative treatment. The patient had no past history of trauma, tuberculosis, chronic granulomatous disease etc. His MRI was suggestive of pigmented villo nodular synovitis so he was operated to relieve symptoms and disability. The patient also complained of pain in small joints of the hands (Fig 2), both wrist joint pains and morning stiffness of more than 2 hours. He was diagnosed as a case of sero-positive rheumatoid arthritis, 2 years back. He was non compliant with the medications. History of RA and associated PVN synovectomy raised doubt of a possible rheumatoid synovitis of the knee. MRIs and later histopathological reports confirmed the diagnosis of PVN synovitis showing hyperplastic synovium with papillary projections, foamy histiocytes and hemosiderin-laden macrophages. Observations showed large clefts, synovial cell lined alveolar or pseudoglandular spaces.

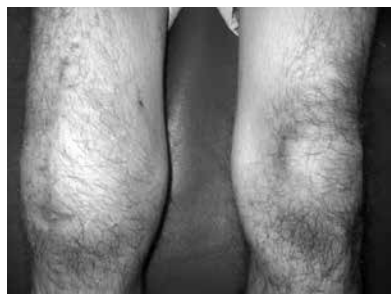

Fig 1: Right knee after open synovectomy

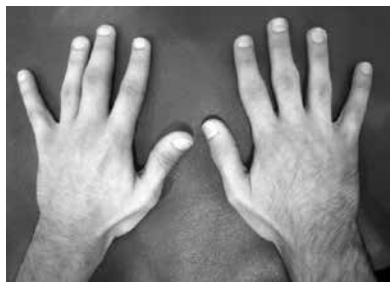


Fig 2: Both hands showing very early RA changes

Normal limits were reported in all base line investigations i.e. random blood sugar (RBS), blood complete picture (CP), liver function tests, urine RE, lipid profile and renal function tests etc. Erythrocyte sedimentation rate (ESR) was 65 mm along with positive RA factor. C reactive proteins and anti CCP antibodies were also positive. His X rays of both hands revealed juxta articular osteopenia. The patient was educated regarding his disease course and management options along with possible complications and was motivated to start regular treatment for RA. Patient was advised Tab methotrexate 10 mg weekly, with folic acid and celecoxib for pain relief. Patient was also prescribed therapeutic exercises and physical therapy. Three weeks of outdoor rehabilitation management led to gradual improvement of patient and he achieved 90-180 degree of a functional motion with reduced clinical symptoms of RA within next 03 months and was also asked to see a rheumatologist regularly for his RA.

## DISCUSSION

Jaffe et al, in 1941, was the first person to label Pigmented villo nodular synovi-

tis.<sup>6</sup> It commonly affects the Knee but other areas including hip, shoulder, ankle and fingers have been widely reported. It has been reported at unusual sites like popliteal fossa, popliteal cyst and fat pad of the knee and at times it leads to misdiagnosis of synovial sarcoma. It has a benign proliferation with deposition of hemosiderin. The exact etiology is not known. PVNS has also been confused with primary synovial epitheloid sarcoma of the knee.<sup>7</sup> PVNS has been found in patients undergoing knee arthroplasty and in one case PVN was found to be the cause of loosening of tibial component, and it was revealed in the revision surgery.<sup>8</sup>

RA is an inflammatory arthritis. A strikingly large synovium is seen in RA, chiefly due to synovial layer hyperplasia, micro vessel proliferation, and synovium infiltration by inflammatory and immune cells including lymphocytes.<sup>3,9</sup>

There has been no reported association between PVN and auto immune disease in the past. There has been only one case report showing PVNS in a case of SLE<sup>10</sup> and one case report showing PVNS in RA.<sup>5</sup> Only future research will reveal whether association among PVNS and RA and SLE is an accidental finding or it really exist that has been previously overlooked.<sup>3</sup>

Scientists have been looking for the pathogenesis and etiology of these different diseases to find some similarity or common pathways. A comparative analysis was performed by Berger et al<sup>11</sup> in 2005, on cell ploidy, phases of cell cycle, macrophages' expression and markers of fibroblast in multiplying synovial cells in RA and PVNS, found that although they are homogenous appearance histologically but their immuno phenotype is heterogeneous both in RA and PVNS. They demonstrated similar phenotypic characteristics about macrophages and fibroblasts functional properties in synovial cells proliferation in PVNS and RA. Aneuploidy was also considered a diffuse PVNS feature.<sup>11</sup>

Youdoh K et al, in 1999, studied different mechanism of synovial hyperplasia in RA and PVNS, and the telomerase activity involvement in proliferation of synovium. They showed that activation of lymphocytes and their proliferation in RA and proliferation of synoviocytes in PVNS may be due to telomerase activity. Proliferation of synovium in RA and advancement of synovitis and synovial villi hyperplasia in PVNS may be influenced by the telomerase activity. It denotes a common link towards the possible pathogenesis and proliferation in both RA and PVNS.<sup>3</sup>

An overlapping pattern of progressing fibroblasts and macrophages was found in a study that compared histopathological characteristics of synovitis in diffuse PVNS and RA. In PVNS, CD68/CD163+ synoviocytes were randomly distributed whereas in patients with RA they were evidently found near synovial lining layer. In diffuse PVNS, aneuploid synoviocytes were 20% whereas diploid synoviocytes were seen in all samples of RA or focal PVNS.<sup>11</sup>

PVN synovitis in RA has been previously documented in literature only once.<sup>11</sup> We did an extensive literature search on pubmed/Medline with the keywords "PVN in RA", "PVNS", "rheumatoid synovitis" and "RA synovitis" but could find only one case of RA with PVNS of the knee by Zhao X et al in 2014.<sup>5</sup> It was diagnosed in 56 years old male with three years history of RA and on regular disease modified anti inflammatory drugs (DMARDs). The patient improved after surgical resection and at one year follow up. In our case the patient was a twenty one year old young man, and on irregular treatment for RA and has been diagnosed two years back.

It might be the first step in exploring the varied pathogenesis of these diseases and their relationship with each other. It also points out towards the association of PVNS with Auto immune diseases like SLE and RA. Despite the similarities

of presentation and homogenous histopathological findings, and evidence of relapse in both cases there are important differences that needs to be mentioned.

1. RA leads to symmetric joint involvement while PVNS usually involves one joint.
2. RA is more common in females while PVNS has equal sex distribution.
3. RA is inflammatory while PVNS<sup>12</sup> is usually non inflammatory.
4. RA shows significant improvement with drug therapy while Surgery is the main stay of treatment in PVNS.<sup>13</sup>

This case report may lead to identification of pathogenesis and establish an association between these two diseases or may turn out to be just a coincident finding of the two diseases in the same patient.

## CONCLUSION

There is lack of literature about the etiology of PVN. As association of PVN with RA is rarely documented, a firm relation between PVN synovitis and RA

cannot be established and needs further extended research.

## REFERENCES

1. Flandry F, Hughston JC. Pigmented villonodular synovitis. *J Bone Joint Surg Am* 1987;69-A:942-9.
2. Flandry F, Hughston JC, McCann SB, Kurtz DM. Diagnostic features of diffuse pigmented villonodular synovitis of the knee. *Clin Orthop Rel Res* 1994;298:212-20.
3. Yudoh K, Matsuno H, Nezuka T, Kimura T. Different mechanisms of synovial hyperplasia in rheumatoid arthritis and pigmented villonodular synovitis. The Role of Telomerase Activity in Synovial Proliferation. *Arthritis Rheum* 1999; 42(4): 669-77.
4. Byers PD, Cotton RE, Deacon OW, Lowy M, Newman PH, Sissons HA, et al. The diagnosis and treatment of pigmented villonodular synovitis. *J Bone Joint Surg Br* 1968;50 B(2):290-305.
5. Zhao X, Ji W, Qian X, Lu Y. Pigmented Villonodular Synovitis Developing in a Patient With Rheumatoid Arthritis. *J Clin Rheumatol* 2014;20(5):283-6.
6. Hughes TH, Sartoris DJ, Schweitzer ME, Resnick DL. Pigmented villonodular synovitis: MRI characteristics. *Skeletal Radiol* 1995; 24:7 12.
7. Chow LTC. Primary synovial epithelioid sarcoma of the knee: distinctly unusual location leading to its confusion with pigmented villonodular synovitis. *APMIS* 2015; 123: 350-8.
8. Chung BJ, Park YB. Pigmented Villonodular Synovitis After TKA Associated With Tibial Component Loosening. *Orthopedics* 2011; 34(8):418-20.
9. Firestein GS. Rheumatoid synovitis and pannus. In: Klippel JH, Dieppe PA, editors. *Rheumatology*. London: Mosby; 1998. p. 1-24.
10. Anders HJ. Pigmented villonodular synovitis of the hip in systemic lupus erythematosus: a case report. *J Med Case Rep* 2011; 5:443-4.
11. Berger I, Weckauf H, Helmchen B, Ehemann V, Penzel R, Fink B, et al: Rheumatoid arthritis and pigmented villonodular synovitis: comparative analysis of cell ploidy, cell cycle phases and expression of macrophage and fibroblast markers in proliferating synovial cells. *Histopathology* 2005;46:490-7.
12. Ottaviani S, Ayril X, Dougados M, Gossec L. Pigmented villonodular synovitis: a retrospective single-center study of 122 cases and review of the literature. *Semin Arthritis Rheum* 2010; 40:539-46.
13. Mankin H, Trahan C, Hornicek F. Pigmented villonodular synovitis of joints. *J Surg Oncol* 2011;103(5):386-9.

### CONFLICT OF INTEREST

Authors declared no conflict of interest

### GRANT SUPPORT AND FINANCIAL DISCLOSURE

NIL

KMUJ web address: [www.kmuj.kmu.edu.pk](http://www.kmuj.kmu.edu.pk)  
Email address: [kmuj@kmu.edu.pk](mailto:kmuj@kmu.edu.pk)