

HISTOLOGICAL EFFECTS OF ISONIAZID ON THE LIVER OF ALBINO MICE

Farhat Humayun¹✉, Mohammad Tahir², Khalid Parvez Lone²

¹Basic Medical Sciences Department, Majmaah University, Al-Majmaah, Kingdom of Saudi Arabia
Email: 3maanbrothers@gmail.com
Phone #: +966530468266
² University of Health Sciences, Lahore, Pakistan
Date Submitted: October 07, 2015
Date Last Revised: June 09, 2017
Date Accepted: June 10, 2017

ABSTRACT

OBJECTIVE: To investigate the effects of thirty days of isoniazid administration on histology of adult male albino mice liver.

METHODS: Forty healthy adult male mice were obtained from the Veterinary Research Institute Lahore and were kept in the animal house facility of University of Health Sciences, Lahore, Pakistan. Animals were fed on normal mouse diet and water ad libitum. Mice were divided into two groups, i.e. group A & B. Group A served as a control and received 10ml/kg of distilled water while group B served as experimental and treated with isoniazid 100mg/kg body weight for 30 days. At the end of the experiment liver was dissected and processed for light microscopy. Serial sections of liver 4µm thick were stained with Harris Hematoxylin & Eosin and Periodic Acid Schiff (PAS) for microscopic examination.

RESULTS: No obvious gross abnormalities were present in either control or experimental group. Group A showed the normal liver histology. Group B showed disturbed liver architecture with loss of radial arrangement of hepatic cords and sinusoids. Hepatocyte boundaries were ill-defined. Darkly stained nuclei indicating pyknotic changes. Necrosis evident by pyknosis, karyolysis and karyorrhexis was also observed. Apoptotic bodies were clearly seen and fatty change was evident by signet ring formation. Larger, swollen and empty looking hepatocytes, with the loss of cytoplasmic contents appearing as micro and macro vacuoles were noticed. Vessels were dilated and congested. Periportal and focal areas of inflammation were present.

CONCLUSION: Isoniazid treatment has potential hepatotoxic effects on male albino mice causing disturbed liver architecture.

KEY WORDS: Isoniazid (MeSH), Necrosis (MeSH), Apoptosis (MeSH), hepatotoxic (Non-MeSH), Antitubercular Agents (MeSH).

THIS ARTICLE MAY BE CITED AS: Humayun F, Tahir M, Lone KP. Histological effects of isoniazid on the liver of Albino mice. *Khyber Med Univ J* 2017; 9(2): 68-71.

INTRODUCTION

Tuberculosis is the primary cause of mortality among people with low immunity. Using the drug regimen of Isoniazid, Rifampicin, Ethambutol and Pyrazinamide; many countries have successfully increased the rate of their tuberculosis treatment, but the side effects of these anti tuberculous drugs continue to threaten global tuberculosis control efforts. Isoniazid, also renowned as isonicotinyl hydrazine (INH) is the

first drug of choice for prevention and treatment of tuberculosis. In 1951 it was establishing to be useful against *Mycobacterium tuberculosis*.¹

Anti-tuberculosis drug pharmacokinetics is predisposed by patient age, sex, origin and GIT infections. Isoniazid is freely absorbed from the GIT and produces highest blood levels in 1 to 2 hours, when administered orally. It easily spreads to the cells, tissues, organs and body waste (saliva, sputum, and feces). It

is excreted mainly by kidneys and also by feces.²

Isoniazid is a drug when administered, is in an inactive form; it is metabolized in the body into a biologically active compound. It is activated by a bacterial catalase-peroxidase enzyme which in tuberculosis is called as KatG, which pairs the isonicotinic acyl with nicotinamide adenine dinucleotide (NADH) to form isonicotinic acyl-NADH complex. This compound sticks firmly to the enoyl-acyl carrier protein reductase (key enzyme in type II fatty acid synthesis) known as InhA, so blocking the natural enoyl-AcpM substrate and the action of fatty acid synthase. This procedure inhibits the production of mycolic acid, which is required for the mycobacterial cell wall synthesis.³ Isoniazid is bactericidal to quickly-dividing mycobacterium but is bacteriostatic if the mycobacterium is slowly dividing.⁴

Toxicity of isoniazid has been related with intense seizures, peripheral neuropathy, hepatomegaly, blood disorders, allergy, psychological disorders, immunologic and gastrointestinal disorders.^{5,6} Amongst them; hepatotoxicity is the severest one and is the center of attention of the present study.

Isoniazid hepatotoxicity ranges in severity from asymptomatic elevation of serum transaminases to hepatic failure. Isoniazid is directly or indirectly metabolized to acetyl hydrazine and hydrazine by N-acetyltransferase and amidohydrolase. Acetyl hydrazine and hydrazine might be oxidized by Cytochromes P450 (CYPs) to form hepatotoxic metabolites.⁷

Human genetic studies have shown that cytochrome P4502E1 (CYP2E1) is involved in anti-tubercular drug hepatotoxicity. The CYP2E1 c1/c1 genotype is associated with a higher CYP2E1 activity

and may lead to a greater production of hepatotoxins. Experimental studies on rats showed that Isoniazid and Hydrazine induce CYP2E1 activity. Isoniazid has an inhibiting effect on CYP1A2, 2A6, 2C19 and 3A4 activity. CYP1A2 is suggested to be involved in hydrazine detoxification.⁸ Isoniazid can induce its own toxicity, possibly by the induction or inhibition of these enzymes;⁸ the toxic effects of isoniazid on liver histology were evident by necrosis, apoptosis, fatty changes, focal central vein congestion, portal inflammation and loss of cellular boundaries.⁹

Previous studies generally reported the preventive effects of many drugs and herbs on isoniazid induced hepatotoxicity.¹⁰ The current study was conducted to investigate the actual architectural damage to liver tissue on consumption of isoniazid in male albino mice.

METHODS

It was an experimental study. Simple random sampling by balloting method was used. Study was conducted on 40 non-tuberculous healthy male albino mice, which were obtained from Veterinary Research Institute (VRI), Lahore, Pakistan and were kept in an animal house of University of Health Sciences, Lahore; Pakistan. This research on experimental animals was approved by Ethical Review Committee for Medical and Biomedical research, University of Health Sciences; Lahore, Pakistan.

Inclusion Criteria:

Healthy adult male mice, 6-8 weeks of age, weighing $30g \pm 5g$ were taken. They were divided into two groups A and B. Each group was housed in an individual stainless steel cage with wood shavings at the floor in the experimental research laboratory at controlled room temperature ($23 \pm 2^\circ C$), humidity ($50 \pm 5\%$) and light and dark cycles of 12 hours each. Cage cards were used indicating identity regarding groups of the animals and their number. The animals were fed on standard mouse diet (wheat balls) and water ad libitum.

Exclusion Criteria:

The experiment was started after acclimatization period of 1 week. Dis-

eased animals, mice older than 8 weeks and with weight more than 35g were excluded from the experiment.

Experimental Design:

Group A served as control and consisted of fifteen mice. Group B was experimental and consisted of twenty-five animals. Group A was fed on normal mouse diet, water ad libitum and each mouse was given additionally 10 ml/kg of distilled water by mouth for 30 days. Group B was administered isoniazid orally in a single daily dose of 100mg/kg for 30 days to produce hepatotoxicity.

Isoniazid was obtained in powdered form, from Sigma Chemicals Company (St. Louis, MO, USA). Dose of isoniazid was based on previous studies in which isoniazid was given at 100 mg/kg/day, orally for 30 days,^{9,11} dissolved in 10 ml distilled water,¹² using mouse as experimental models.

The animals were dissected on the 30th day of experiment. The livers of the mice were removed soon after sacrificing the animals and 3-5 mm thick pieces were excised after gross examination of the organ. Livers were fixed in formalin solution for 2 days and processed to prepare paraffin blocks. $4\mu m$ thick serial sections of liver were obtained and stained with Haematoxylin and Eosin (H & E) and Periodic Acid Schiff's (PAS) stains.

RESULTS

Gross features

On gross examination, the liver was smooth in texture. It was dark brown in color, with four lobes, surrounded by thin layer of connective tissue capsule. Obvious gross abnormalities were not present either in control or treated group.

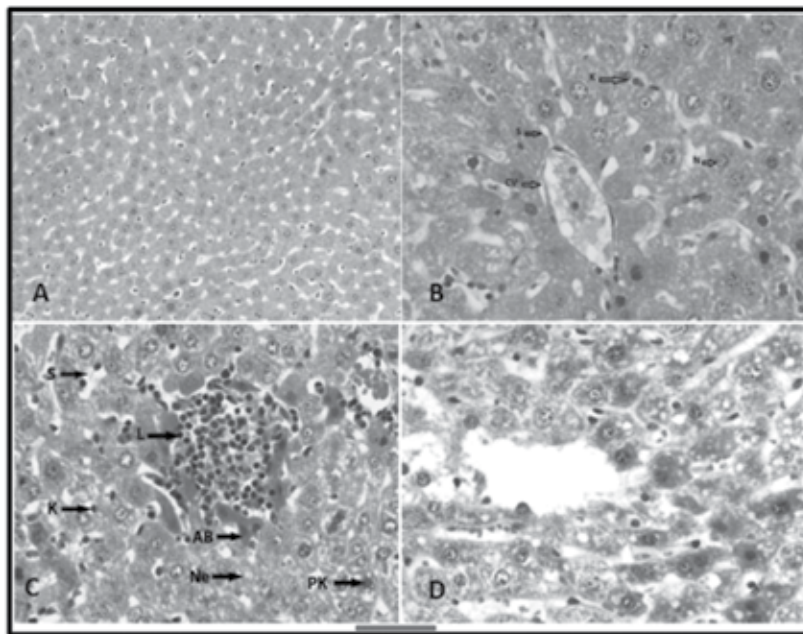


Figure 1A: Liver section from group A, showing radiating hepatic cords with sinusoids in between them (H & E Stain. Scale bar is $100 \mu m$ approximately)

Figure 1B: Liver section from group A. Round to polyhedral hepatocytes having vesicular nucleus (N) with clear nuclear membrane are seen. Sinusoids (S) are opening in the central vein (CV). Kupffer cells (K) are seen in the lining of the sinusoids. A few binucleated hepatocytes are also seen in the micrograph. (H & E Stain. Scale bar is $50 \mu m$ approximately)

Figure 1C: Liver section from group B. Areas of necrosis (Ne) evident by fragmented and pyknotic nuclei (PK). Focal collection of lymphocytes (L) and apoptotic bodies (AB) can be seen. Kupffer cells (K) with prominent nuclei projecting in sinusoids (S) are also visible. (H & E Stain. Scale bar is $50 \mu m$ approximately)

Figure 1D: Liver section from group B. There is steatotic hepatic change with vacuolar degeneration and signet ring appearance. (H & E Stain. Scale bar is $50 \mu m$ approximately)

Histological features

Typical hepatolobular architecture was observed in the control group A under 10, 20 and 40 X objectives. Hepatocytes were rounded to polyhedral in shape; having single or double nuclei, with clear nuclear membranes (Figure 1B). Normal hepatic lobules with central vein and peripheral portal triads were seen. The hepatic cells were arranged as cords radiating from central veins to the periphery with sinusoids in between them (Figure 1A). Scattered kupffer cells with cytoplasmic processes and rounded prominent nuclei were also observed. The hepatic sinusoids were seen to be anastomosing irregularly with each other and opening into the lumen of central vein (Figure 1B). Small cytoplasmic vacuoles of variable sizes and shapes, presumably indicating glycogen or fatty content of the cytoplasm were noticed in the hepatocytes. Vesicular nucleus with 1-2 nucleoli was recorded. Some nuclei were pyknotic.

Portal area comprised of tributary of portal vein, branches of hepatic artery and bile duct. The portal vein tributary had wide, endothelial lined lumen containing erythrocytes; the hepatic artery branch had narrow lumen and thicker wall. Bile duct branch was lined by low cuboidal epithelium. No periportal inflammation was observed.

In the treated group B, liver architecture was disturbed with loss of radial arrangement hepatic cords and sinusoids. Hepatocyte boundaries were illdefined. Darkly stained nuclei indicating pyknotic changes and clumping of nuclear material were recorded in this group. Necrosis evident by pyknosis, karyolysis and karyorrhexis was also an observable feature of this group. Apoptotic bodies were clearly seen and fatty change was evident by signet ring formation (Fig 1-C). Larger, swollen and empty looking hepatocytes, with the loss of cytoplasmic contents appearing as micro and macro vacuoles, were noticed in this group (Fig 1-D). Vessels were dilated and congested.

Periportal and focal areas of inflammation were present.

DISCUSSION

The histological observations on liver from treated group showed marked changes. It was observed that the general architecture of liver in isoniazid group was deranged, possibly on account of hepatocyte swelling. These results are similar to a previous study, in which rats treated with isoniazid shows hepatocellular disintegration and vacuolation in centrilobular region.¹³ This loss of radial arrangement of hepatocytes along with hypertrophy of cells and ballooning degeneration was also reported in previous by Noorani et al. (2010) who observed that isoniazid caused liver damage in albino rats.¹⁴ Bhadauria et al. (2007) reported that subchronic administration of CCl_4 caused degeneration and disintegration of liver cell architecture.¹⁵ In his study, hepatic lesions were characterized by massive hepatic necrosis and a large vacuolation.

In our study, in group B, INH caused necrosis, pyknotic nuclei without nucleoli and at some places fragmented nuclei were present; these were indicative of degenerative changes and toxic effects of INH on liver. Pyknosis is the irreversible condensation of chromatin in the nucleus of a cell undergoing apoptosis. Pyknotic nuclei appear as dark and condensed chromatin material (Figure 1; C and D).

The histopathological features of INH produced hepatotoxicity were characterized by focal inflammatory infiltration, necrosis, and vacuolization and ballooning degeneration¹⁶. In our study, mice in experimental group B also showed lymphocytic infiltration around bile duct called periportal inflammation (Fig 1-C and D). The histological preparation of the liver from group B also showed empty spaces, indicative of degeneration of hepatocytes and/or an increased content of fat which was removed during the process of preparation of slides. It has been reported that toxic isoniazid

metabolites bind covalently to cell macromolecules. Hydrazine is the toxic metabolite of isoniazid, which is metabolized by cytochrome P-450 system in the liver. Hepatotoxicity could be due to any disturbance in cytochrome P-450 system or in detoxification pathway. Hydrazine causes steatosis and hepatocyte vacuolation.⁸

It had been reported previously that animals receiving isoniazid showed periportal inflammation, fatty changes, liver cell necrosis, ballooning degeneration, vascular congestion, pyknosis and apoptosis.^{1,17-19}

Both human and animal experimental studies proved that it is manifested mainly as hepatocellular steatosis, ballooning degeneration and minimal cholestasis and it has been recommended that toxic isoniazid metabolites bind covalently to cell macromolecules.¹⁷ Hydrazine is the toxic metabolite of isoniazid and is reported to produce hepatocyte vacuolar degeneration and necrosis.⁹ Lipid vacuoles along with mitochondrial swelling are found in hepatocytes; both periportal and midzonal as reported by Tostmann et al. (2008)⁸. In another study, diffuse micro vesicular fatty infiltration with mild portal triaditis and moderate to heavy lobular inflammation and piecemeal necrosis was reported.²⁰ Kupffer cell hyperplasia had also been observed by Bigonyia et al. (2009) along with fibrosis and nodular regeneration.¹³ Anbarasu et al. (2011) observed in an experiment that INH produced enlargement of liver.²¹

CONCLUSION

It is concluded that Isoniazid has potential hepatotoxic effects on male albino mice causing disturbed liver architecture.

ACKNOWLEDGEMENT

We are grateful to SIGMA Company who provided the drug required for our experiment. We are also obliged to HEC who provided necessary funds for the investigations.

REFERENCES

- Maryam S, Aziz K, Bhatti ASA, Shahzad AW. Effects of jetepar (glucometamine, glucodiamine and nicotinamide ascorbate) on isoniazid induced hepatotoxicity in rabbits. *Ann King Edward Med Uni* 2010;16(1):37-42.
- Sekai C, Carla AW, Charles AP, William ZB, Philip CH, Charles DW, et al. Isoniazid, Rifampin, Ethambutol, and Pyrazinamide Pharmacokinetics and Treatment Outcomes Among a Predominantly HIV-Infected Cohort of Adults with Tuberculosis from Botswana. *Clin Infect Dis* 2009;48(12):1685-94.
- Khan SR, Morgan AG, Michail K, Srivastava N, Whittal RM, Aljuhani N, et al. Metabolism of isoniazid by neutrophil myeloperoxidase leads to isoniazid-NAD⁺ adduct formation: a comparison of the reactivity of isoniazid with its known human metabolites. *Biochem Pharmacol* 2016;106:46–55. doi: 10.1016/j.bcp.2016.02.003. Epub 2016 Feb 9.
- Steven TP, Jon CA, Rebecca D, Kim AH, Rose EJ, Charlotte LHD, et al. The effect of growth rate on pyrazinamide activity in *Mycobacterium tuberculosis* - insights for early bactericidal activity. *BMC Infect Dis* 2016;16(1):205.
- Horsburgh JCR, Barry CE, Lange C. Treatment of tuberculosis. *N Engl J Med* 2015 Nov 26;373(22):2149-60. doi: 10.1056/NEJMr1413919.
- Villarino ME, Scott NA, Weis SE, Weiner M, Conde MB, Jones B, et al. The International Maternal Pediatric and Adolescents AIDS Clinical Trials Group (IMPAACT) and the Tuberculosis Trials Consortium (TBTC). Treatment for Preventing Tuberculosis in Children and Adolescents. A Randomized Clinical Trial of a 3-Month, 12-Dose Regimen of a Combination of Rifampentine and Isoniazid. *JAMA Pediatr* 2015;169(3):247-55.
- Kalra BS, Aggarwal S, Khurana N, Gupta U. Effect of cimetidine on hepatotoxicity induced by isoniazid-rifampicin combination in rabbits. *Indian J Gastroenterol* 2007;26(1):18-21.
- Tostmann A, Boeree MJ, Aarnouts RE, Dekhuijzen R. Antituberculosis drug – induced hepatotoxicity. *J Gastroenterol Hepatol* 2008;23(2):192-202.
- Jehangir A, Nagi AH, Shahzad M, Zia A. The hepatoprotective effect of Cassia fistula (amaltas) leaves in isoniazid and rifampicin induced hepatotoxicity in rodents. *Biomedica* 2010;26(1):25–9.
- Jahan S, Khan M, Imran S, Sair M. The hepatoprotective role of Silymarin in isoniazid induced liver damage of rabbits. *J Pak Med Assoc* 2015 Jun 1;65(6):620-3.
- Rao GN, Lindamood C, Heath JE, Farnell DR, Giles HD. Sub chronic toxicity of human immunodeficiency virus and tuberculosis combination therapies in B6C3F1 Mice. *Toxicol Sci* 1998;45(1):113-27.
- Cynamon MH, Sklaney M. Gatifloxacin and ethionamide as the foundation for therapy of tuberculosis. *Antimicrob Agents Chemother* 2003;47(8):2442–4.
- Bigoniya P, Singh CS, Shukla A. A comprehensive review of different liver toxicants used in experimental pharmacology. *Int J Pharm Sci Drug Res* 2009;1(3):124-35.
- Noorani AA, Saini N, Saini K, Kale MK. Hepatoprotective effect of rimonabant against isoniazid induced liver damage in albino wistar rats. *Int J Pharm Biol Sci Arch* 2010;1(05):473-7.
- Bhadauria M, Nirala SK, Shukla S. Hepatoprotective efficacy of propolis extract: A biochemical and histopathological approach. *Int J Pharm Technol* 2007;6(2):145-54.
- Sambrekar SN, Patil PA, Kangralkar VA. Protective effect of Embelia Tsjeriam – Cottam fruit extracts on isoniazid induced hepatotoxicity in wistar rats. *Int J Pharm Sci Res* 2010;4(1):136-9.
- Kalra BS, Aggarwal S, Khurana N, Gupta U. Effect of cimetidine on hepatotoxicity induced by isoniazid-rifampicin combination in rabbits. *Indian J Gastroenterol* 2007;26(1):18-21.
- Tandon VR, Khajuria V, Kapoor B, Kour D, Gupta S. Hepatoprotective activity of Vitex negundo leaf extract against anti-tubercular drugs induced hepatotoxicity. *Fitoterapia* 2008;79(7):533-8.
- Kale BP, Kothekar MA, Tayade HP, Jaju JB, Mateen-ud-Din M. Effect of aqueous extract of azadirachta indica leaves on hepatotoxicity induced by anti-tubercular drugs in rats. *Indian J Pharmacol* 2003;35(3):177-80.
- Pal R, Vaiphei K, Sikander A, Singh K, Rana SV. Effect of garlic on isoniazid and rifampicin – induced hepatic injury in rats. *World J Gastroenterol* 2006;12(4):636-9.
- Anbarasu C, Rajkapoor B, Kalpana J. Protective effect of *Pisonia aculeate* on rifampicin and isoniazid induced hepatotoxicity in rats. *Inter J Phytomed* 2011;3(1):75-83.

CONFLICT OF INTEREST

Authors declared no conflict of interest

GRANT SUPPORT AND FINANCIAL DISCLOSURE

Drugs required for study were supplied by SIGMA Company and necessary funds for the investigations were provided by Higher Education commission (HEC), Pakistan

AUTHORS' CONTRIBUTION

Following authors have made substantial contributions to the manuscript as under:

FH: Acquisition, analysis and interpretation of data, drafting the manuscript, final approval of the version to be published.

MT: Drafting the manuscript, final approval of the version to be published.

KPL: Concept & study design, critical revision, final approval of the version to be published.

Authors agree to be accountable for all aspects of the work in ensuring that questions related to the accuracy or integrity of any part of the work are appropriately investigated and resolved.