

# ULTRASONOGRAPHY: A GOOD AID TO THE CLINICAL DIAGNOSIS OF ACUTE APPENDICITIS

Fazal Ahmed<sup>1</sup>, Mohammad Tahir<sup>1</sup>, Qazi Tahir Ud-din<sup>1</sup>, Ejaz Ahmed Khan<sup>2</sup>, Nafisa Batool Tahir<sup>3</sup>, Shahid Sardar<sup>4</sup>, Bakhtiar Ahmad<sup>5</sup>

## ABSTRACT

**Objective:** to evaluate the value of ultrasonography in the diagnosis of acute-appendicitis, in clinically suspected cases.

**Methodology:** This prospective observational study was carried out at DHQ Teaching hospital, Khyber Medical University, Institute of Medical Sciences Kohat, Pakistan from Feb-2009 to Nov-2011. This study included 150 patients with a clinical suspicion of acute-appendicitis. The ultrasound findings were compared with histopathological outcome of the case, which was taken as gold standard. In the radiology department, color Doppler ultra sound machine, Accucie Toshiba with a 7.5 MHz, abdominal probe was used. All the exams were performed by a single senior radiologist.

**Results:** Out of 150 patients, 112 (74.7%) were male and 38 (25.3%) were female. Age ranged from 12 to 60 years. On the basis of ultrasonography, 100 (66.7%) patients were labeled as positive for acute-appendicitis and 50 (33.3%) patients as negative for acute-appendicitis. Out of 100 positive patients, 79% patients were confirmed as acute-appendicitis on histopathology and 21% had normal appendix on histopathology. Out of 50 negative patients, 12 (24%) patients had right ureteric calculus and 6 (12%) patients had acute cholecystitis while 5 (10%) patients were explored later on because of persistent pain and progressing symptoms and a diagnosis of acute-appendicitis was confirmed on histopathology.

**Conclusion:** In clinically suspected cases of pain right iliac fossa, the use of ultrasonography is valuable to establish acute appendicitis or alternate diagnosis. It can be recommended as a valuable screening tool in clinically suspected cases of acute-appendicitis.

**Key Words:** Ultrasonography, acute appendicitis, histopathology.

**This article may be cited as:** Ahmed F, Tahir M, Uddin QT, Khan EA, Tahir NB, Sardar S, et al. Ultrasonography: A good aid to the clinical diagnosis of acute appendicitis. Khyber Med Univ J 2012; 4(4): 165-169.

## INTRODUCTION

With the introduction of ultrasound in late 20th century, it has revolutionized the diagnostic armamentarium of many abdominal surgical conditions, specially the emergency cases like acute appendicitis, because of its wide and ready availability, low cost, no radiation risk and continuous technological improvement in quality<sup>1</sup>. Although the CT scan is considered the diagnostic modality of choice at many modern hospitals and medical

practices, with its new helical scanners which can diagnose or exclude acute appendicitis with high sensitivity and specificity, the ultrasound provides the most practical method of imaging investigation in a peripheral hospital setting with restricted availability of costly diagnostic tools such as a modern CT Scan machine. The graded compression technique has significantly improved sensitivity and specificity of ultrasound and it is recommended as a routine test in the investigation of acute appendicitis<sup>2</sup>. Sometimes plain X-rays abdomen and urine analysis are done to further exclude the urinary causes of right loin pain; however they have low sensitivity and specificity in making a positive diagnosis of acute appendicitis.

Laboratory investigations like total and differential leucocytic counts are also helpful in the diagnosis of acute appendicitis<sup>3</sup>. In the last two decades, sonography has shown promising results in the diagnosis of acute-appendicitis. Studies have shown the sensitivity and specificity of ultrasound in the diagnosis of appendicitis as 80% and 90% respectively.<sup>4</sup> Ultrasonography (US) is helpful in establishing the diagnosis and confirmation of acute appendicitis and at times helps in excluding an alternate diagnosis. However normal ultrasound cannot rule out appendicitis.<sup>5,6</sup> Acutely inflamed appendix is non-compressible, shows increased thickness, dilatation

1. Assistant Professor Surgery, Khyber Medical University (KMU), Institute of Medical Sciences Kohat, Pakistan
2. Assistant Professor Community Medicine, KMU Institute of Medical Sciences Kohat, Pakistan
3. Assistant Professor Medicine, KMU Institute of Medical Sciences Kohat, Pakistan
4. Assistant Professor Radiology, KMU Institute of Medical Sciences Kohat, Pakistan
5. Consultant Radiologist, Medical Imaging Department, King Abdul Aziz Hospital (National Guard Health Affairs), Al Ahsa31982Kingdom of Saudi Arabia

### Address for Correspondence:

**Dr. Fazal Ahmed**

Assistant Professor Surgery, KMU Institute of Medical Sciences Kohat, Pakistan

Email: surfazal@gmail.com

**Date Submitted:** March 06, 2012

**Date Last Revised:** November 26, 2012

**Date Accepted:** November 28, 2012

and peri-appendiceal inflammation and on color Doppler shows increased vascularity. The inaccurate negative reports sometimes may be due to increased bowel gases, stool loaded gut or obesity. In the past, studies have been done on routine use of ultrasonography in patients with pain right iliac fossa and these had revealed high sensitivity and specificity as compared to clinical judgment, thus reducing negative explorations. Now-a-days new ultrasound machines are very accurate in picking up the signs of appendicitis. Sonography has proved its cost effectiveness by minimizing unnecessary operations.

In Pakistan, few studies have been conducted to determine the diagnostic value of abdominal ultrasound in acute appendicitis.<sup>7-9</sup> This study was carried out at a peripheral district headquarter hospital with limited diagnostic facilities, to evaluate the role of abdominal ultrasound in the clinically suspected cases of acute appendicitis.

### METHODOLOGY

In present study, we selected 150 patients who had presented with pain right iliac fossa (RIF), a clinical diagnosis of acute appendicitis was made on history and physical examination, which included pain starting in paraumbilical area and then shifting to right iliac fossa, nausea, vomiting and tenderness in right iliac fossa. Out of these one hundred patients, 112 were males and 38 were females and their age ranged from 12--60 years. Prompt surgical intervention was carried out in all those cases, where the ultrasonic diagnosis of acute appendicitis was established. We excluded from study all the cases, which on presentation had appendicular mass or had generalized peritonitis from perforated appendix. All the patients underwent sonographic examination with the help of Accucie Toshiba machine, with a 7.5 MHz high resolution probe. Complete examinations were performed by a single senior radiologist and he was provided with the information of clinical suspicion of acute appendicitis before performing the study. All operated specimens of appendix were submitted for histopathology study. Data analysis carried for specificity and sensitivity. Results were compared with other studies. The following criteria were considered for the sonographic diagnosis or exclusion of acute appendicitis:

- 1: Non visualization of appendix suggestive of negative study.
- 2: On visualization of appendix the diameter equal to or less than 6mm considered as normal.
- 3: Demonstration of enlarged, tubular, blind ending structure with wall thickness of 3.0 mm or diameter of 7.0 mm or more as positive diagnosis of acute appendicitis.
- 4: Loss of wall layers is equal to gangrenous appendicitis.

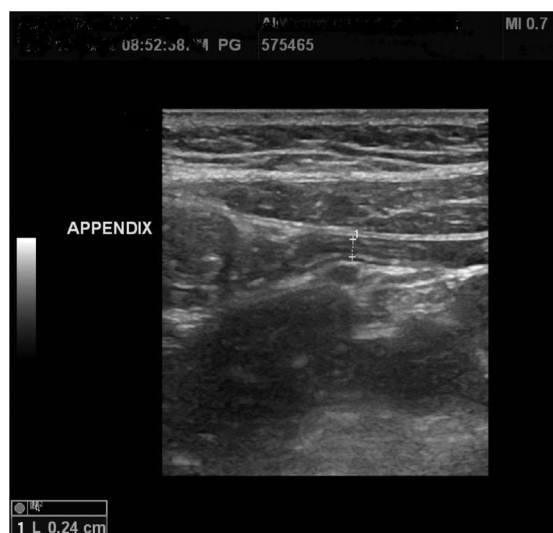

Figure 1. A 16 years male patient with normal appendix on ultrasound. Ultrasound shows a well- defined smooth walled tubular structure (arrows) with diameter less than 6mm and no peri-appendiceal inflammation.

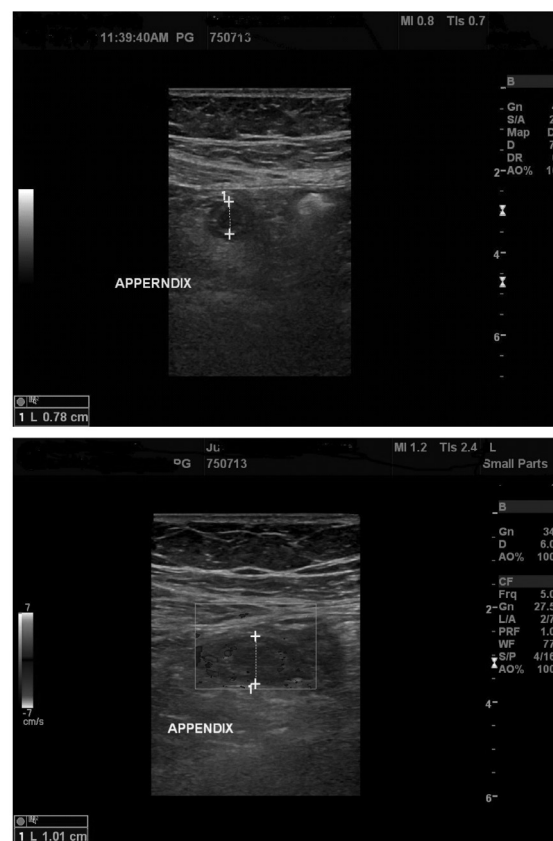


Figure 2. A (top) Acute appendicitis in a 19 years male on ultrasound. There is an enlarged appendix with thick wall, increased diameter, on this cross sectional image shows target sign. (Bottom) Periappendiceal inflammation and increased vascularity on color Doppler.

**DIAGNOSIS OF 100 ULTRASONOGRAPHY POSITIVE CASES OF ACUTE APPENDICITIS.**

Diagnosis	No of cases	Counter confirmation
Acute Appendicitis	79	Histopathologically
Ascariasis	15	Per operatively
Nil Diagnosis	6	Per operatively

Table I

**DIAGNOSIS OF 50 CASES WHICH WERE ULTRASOUND NEGATIVE FOR ACUTE APPENDICITIS**

Diagnosis	No of cases	Percentage of cases
Acute Appendicitis	05	10%
Acute Cholecystitis	06	12%
Right Ovarian Cyst	03	06%
Mesenteric Lymphadenitis	04	08%
Right Ectopic gestation	01	02%
Right Ureteric Calculus	12	24%
Ascariasis	05	10%
Nil Diagnosis	14	28%

Table II

**DIAGNOSIS OF ALL 150 CASES SELECTED FOR STUDY**

Diagnosis	No of cases	Percentage of cases
Acute Appendicitis	84	56.6%
Acute Cholecystitis	06	04%
Right Ureteric Calculus	12	08%
Right Ovarian Cyst	03	02%
Right Ectopic gestation	01	0.66%
Mesenteric Lymphadenitis	04	2.66%
Ascariasis	20	13.3%
Nil Diagnosis	20	13.3%

Table III

**RESULTS**

According to the study inclusion criteria, 150 patients in age range of 12 to 60 years were selected. Out of 150 patients, 112 (74.67%) were males and 38 (25.33%) were females.

Out 150 patients, 100 were positive for acute appendicitis on ultrasonography while 50 were negative, the sensitivity and specificity was tested in these selected cases for the ultrasonography. Selected photographs of patients with normal appendix and inflamed appendix are

given as Figure 1 and 2.

Results show that 79 % cases were diagnosed as acute appendicitis histopathologically which were reported as acute appendicitis on sonography while 21% were false positive for acute appendicitis (Table-I).

Out of 50 cases reported as negative for acute appendicitis, 5 (10%) were operated later and were diagnosed as acute-appendicitis confirmed histopathologically while 90% cases were true negative for appendicitis ultrasonographically as they were managed for other diseases, details given in table Table-II.

In total 84 cases were diagnosed as acute appendicitis histopathologically out of which 79 were true positive and 05 were false negative showing a sensitivity of 94 % for ultrasonography in diagnosing acute appendicitis where as the specificity of this investigation was 68.18 % (Table-III).

**DISCUSSION**

The diagnosis of acute appendicitis mainly depends upon patient history and surgeon’s clinical examination alone in majority of the typical cases of acute appendicitis. However in atypical presentations, in extreme of ages and in pregnant women, clinician needs help from investigations<sup>10-12</sup>. Sometime the inflammation is confined to the tip of appendix and the organ may not be visualized<sup>13,14</sup> with sonography. In present study too, one such case was missed and later on operated because of continuing and progressive symptoms and proved to be one of the false negative case. During pregnancy the clinical diagnosis of acute appendicitis becomes very difficult especially in the third trimester. In these cases, sonology is done in left lateral decubitus position thereby displacing enlarged uterus to the left and making appendix visualization possible<sup>15</sup>. In children and in geriatric patients, sonology is of special help because the symptoms are very vague.<sup>7</sup> Computed tomography has definitely increased the diagnostic accuracy<sup>16</sup> but its availability varies from place to place and moreover it is an invasive diagnostic tool with a reasonably high cost. Ultrasonography has been used extensively as a first line diagnostic tool in clinically suspected cases of acute appendicitis. Since 1986 many workers studied the value of ultrasonography in acute appendicitis and reported its enhanced diagnostic accuracy<sup>17-19</sup>.

Authors studied the role of ultrasonography though a different angle, but the results are comparable. The procedure of present study was different from all others so far published literature on the subject. In over study the prompt surgical intervention in all sonographically diagnosed cases of acute appendicitis, irrespective of Alvarado scoring made the results of ultrasound much more reliable and the values thus obtained regarding sensitivity and specificity of this investigation in acute appendicitis patients are much more authentic.

In past, when clinical suspicion of acute appendicitis was the sole diagnostic criteria, surgeons used to perform appendectomy on border line cases to avoid the complication associated with delayed or missed diagnosis of acute appendicitis. This protocol can lead to up to 20% of negative appendectomies<sup>9</sup>. This protocol and the ratio of negative appendectomies were acceptable all over the world till the availability of ultrasound, CT scan and laparoscopy, which revolutionized this concept, by reducing the ratio of negative laporatomies.

In many studies the sensitivity has been reported in the range of 85-94%.<sup>18,20,21</sup> This investigation has another very important role in clinically equivocal cases where it is helpful in establishing an alternate diagnosis<sup>22,23</sup>. In this study too, authors were able to make an alternate diagnosis in 21% of originally suspected cases for acute appendicitis. Many of these patients with alternate diagnosis did not need surgery and ultrasonography alone reduced the number of negative appendectomies.

A modern ultrasound machine and an experienced sonologist is considered as primary requisite for such type of investigational study. Authors have both facilities available; otherwise it would not have been possible to be so confident for surgeon to operate on the basis of ultrasound report only. Some of the previous reports,<sup>24</sup> which have shown less accuracy for this investigation, were actually having the operator problem.

## CONCLUSION

In clinically suspected cases of pain right iliac fossa, the use of ultrasonography is valuable to establish acute appendicitis or alternate diagnosis. It can be recommended as a valuable screening tool in clinically suspected cases of acute-appendicitis.

## REFERENCES

- Baensler EHL, Jeffery J.R.B, Liang FF. Sonography in patients with suspected acute appendicitis. Value in establishing alternative diagnosis. *Am J Roentgenol* 1989; 152: 49-52.
- Boubalos A. diagnosis of epigastric appendicitis based on sonographic findings. *Am J Roentgenol* 1992; 159:222.
- Chan I, Bicknell SG, Graham M, Utility and Diagnostic accuracy of sonography in detecting appendicitis in a community hospital. *Am J Roentgenol*. 2005; 186(6); 1809-12.
- Garba S, Ahmed A. Appendicitis in the Elderly, Appendicitis - A Collection of Essays from Around the World, Dr. Anthony Lander (Ed.), 2012; InTech, Available from: <http://www.intechopen.com/books/appendicitis-a-collection-of-essays-from-around-the-world/appendicitis-inthe-elderly>
- Naoum JJ, Mileski WJ, Daller JA. The use of abdominal computed tomography scan decreases the frequency of misdiagnosis in cases of suspected appendicitis. *Am J Surg* 2002; 184:587-9.
- Patrick DA, Janik JE, Janik JS. Increased CT scan utilization does not improve the diagnostic accuracy of appendicitis in children. *J Pediatr Surg* 2003; 38:659-62.
- Mardan MAA, Mufti TS, Khattak IU, Chilkunda N, Alshayeb AA, Mohammad AM, et al. Role of ultrasound in acute appendicitis. *J Ayub Med Coll* 2007;19(3):72-9.
- Qureshi IA, Tarin BA, Shafiq M. Role of Ultrasonography in clinically suspected cases of Acute Appendicitis. *Pak Armed Forces Med J* 2001;51(2):90-3.
- Siddiqui ZR, Khaliq T, Shah SA. A new simple scoring system for the diagnosis of acute appendicitis. *J Pak Med Stud* 2011; 1(2): 32-7.
- Dholia KR, Baloch I, Shaikh S A, Soomro S H, Abro A. Total and differential leucocyte count (TLC and DLC) in cases of acute appendicitis: A study of 200 cases at Chandka Medical College Hospital Larkana. *Med Channel* 2010; 16(2):284-6.
- Franke C, Bohner H, Yang Q, Ohmann C, Rohr HD. Ultrasonography for the diagnosis of acute appendicitis: Results of a prospective multicenter trial. *World J Surg* 1999; 23(2); 141-6.
- Haydan CK, Kuchelmeister J, Liposcamp TS. Sonography of acute appendicitis in childhood. Perforation versus non perforation. *J Ultrasound Med* 1992; 11: 209-16.
- Lee JH, Jeong YK, Hwang JC, Ham SY, Yang SO. Graded compression sonography with adjunct use of posterior compression technique in the sonographic diagnosis of acute appendicitis. *Am J Roentgenol* 2002; 178(4):863-8.
- Lee JH, Jeong YK, Park KB, Park JK, Jeong AK, Hwang GC. Operator-dependent techniques for graded compression appendicitis. *Am J Roentgenol* 2005; 184(1): 91-7.
- Lim HK Bar. SH Se OGS. Diagnosis of Acute appendicitis in pregnant women Value sonography. *Am J Roentgenol* 1992; 159: 539-2.
- Nghiem HV, Jeffery JRB. Acute appendicitis confirmed to appendiceal tip. *J Ultrasound Med* 1992; 11: 205-7.
- Ooms HW, Koumans RK, Ho Kang you PJ, Puylaert JB. Ultrasonography in the diagnosis of acute appendicitis. *Br J Surg* 1991; 78(3); 315-8.
- Poole G V. Appendicitis: The diagnostic challenge conclusive. *Am Surgeons* 1998; 5 4: 609-12
- Puylaert JB. Acute appendicitis: US evaluation using graded compression. *Radiology*. 1986; 158(2): 355-60.



20. Ripollés T, Martínez-Perez MJ, Morote V, Solaz J. Diseases that simulate acute appendicitis on ultrasonography. *Br J Radiol* 1998; 71(841): 94-8.
21. Rodríguez DP, Vargas S, Callahan MI, Zurakowski D, Taylor GA. Appendicitis in young children; imaging experience and clinical outcomes. *Am J Roentgenol* 2006; 186(4); 1158-64.
22. Lee S, Walsh AJ, Ho HS. Computed tomography and ultrasonography do not improve and may delay the diagnosis and treatment of acute appendicitis. *Arc Surg* 2001; 136(5); 556-62.
23. Schuler JG, Shortsleeve MJ, Goldenson RS, Perez-Rossello JM, Perlmutter RA, Thorsten A. Is there a role for abdominal computed tomographic scan in appendicitis? *Arch Surg* 1998;133 (4); 373-6.
24. Zielke A, Hasse C, Sitter H, Rothmund M. Influence of ultrasound on clinical decision making in acute appendicitis: a prospective study. *Eur J Surg* 1998; 164(3):201-9.

#### AUTHOR'S CONTRIBUTION

Following authors have made substantial contributions to the manuscript as under:

- FA:** Conception, Acquisition of Data, Final Approval of the manuscript
- MT:** Study Design, Acquisition of data
- QTUD:** Acquisition of data, Drafting the manuscript
- EAK:** Drafting the manuscript
- NBT:** Analysis and interpretation of data,
- SS:** Acquisition of data
- BA:** Critical revision

#### CONFLICT OF INTEREST

Authors declare no conflict of interest

**GRANT SUPPORT AND FINANCIAL DISCLOSURE**  
NONE DECLARED

KMUJ web address: [www.kmuj.kmu.edu.pk](http://www.kmuj.kmu.edu.pk)

Email address: [kmuj@kmu.edu.pk](mailto:kmuj@kmu.edu.pk)